

ORIGINAL ARTICLE

## Effects of wet-to-dry bandages on second intention healing of surgical wounds on the skin of goats

Nooraia Jahan Zinat<sup>1</sup>, Nasrin Sultana<sup>2</sup>, Md. Mansuroh Haq<sup>3</sup>, Md. Mizanur Rahman<sup>1</sup>, Marzia Afrose<sup>4</sup>, Md. Mossabbir Hossain<sup>1</sup>, Md. Rafiqul Alam<sup>1</sup>

<sup>1</sup>Department of Surgery and Obstetrics, Bangladesh Agricultural University, Mymensingh-2202, Bangladesh

<sup>2</sup>Department of Anatomy and Histology, Bangladesh Agricultural University, Mymensingh-2202, Bangladesh

<sup>3</sup>Upazila Livestock Office, Veterinary Surgeon, Habigonj, Bangladesh

<sup>4</sup>Department of Livestock Science and Veterinary Medicine, Bangabandhu Sheikh Mujibur Rahman Science and Technology University, Gopalganj, Bangladesh

### ABSTRACT

**Objectives:** This study aimed to examine the effects of wet-to-dry bandages for the treatment of surgical wounds in goats.

**Materials and Methods:** Three types of bandages, i.e., the calcium alginate gel, the homogenous platelet-rich plasma (PRP) gel dressing, and saline dressing, were used to promote the healing process for the management of wounds. Artificial circular wounds were created and treated with bandages to evaluate their effects on the wound healing process in 12 goats. The morphological parameters, i.e., diameters (cm), duration of healing, and wound contraction (cm), were evaluated to differentiate the postoperative sequelae on wound healing process up to day 30 in three different treatment groups of goats. Tissue specimens from the wounds were examined histopathologically on 1st, 3rd, 7th, and 30th postoperative days. Finally, the obtained data were analyzed using the Statistical Package for the Social Sciences 19 software.

**Results:** The current study revealed that the contraction diameter was higher in calcium alginate gel and PRP gel treated group when compared to the saline dressing group. Aggregation of immunoreactive cells (neutrophils, macrophages, and lymphocytes), collagen fiber bundles among the cells, and proliferation of blood vessels were observed in the epidermis of calcium alginate gel, PRP gel treated and saline dressing wounds, which promote the healing process of wounds. In visual inspection, the number of reactive cells and proliferation of blood vessels were higher in the calcium alginate gel and PRP gel treated group than the saline dressing.

**Conclusion:** In terms of epithelialization, epidermal characteristics, neovascularization, and infiltration of immunoreactive cells, the calcium alginate gel and the homogenous PRP gel dressings showed the best healing performance. Therefore, the present study suggests that clinicians could consider the calcium alginate gel dressing and homogenous PRP gel dressing as beneficial for wound care.

### ARTICLE HISTORY

Received July 20, 2020

Revised September 07, 2020

Accepted September 19, 2020

Published October 07, 2020

### KEYWORDS

Bandages; goat; histological evaluation; surgical wound



This is an Open Access article distributed under the terms of the Creative Commons Attribution 4.0 Licence (<http://creativecommons.org/licenses/by/4.0>)

### Introduction

The wound is a type of injury to the body that occurs from violence, accidents, or surgery that usually entail lacerations or breaking of a skin membrane and damage to underlying tissues, complexed with the involvement of profound structures, i.e., muscles, bones, tendons, nerves,

and vessels [1]. It may be caused by physical, chemical, and thermal means. The factors responsible for the wounds are hypoxia, hypothermia, mechanical stress, anemia, medication, trauma, or pressure [2].

Depending on the source of wound creation, there are two types of wounds, such as open and closed wounds.

**Correspondence** Md. Mizanur Rahman ✉ [miznih@gmail.com](mailto:miznih@gmail.com) 📧 Department of Surgery and Obstetrics, Bangladesh Agricultural University, Mymensingh-2202, Bangladesh.

**How to cite:** Zinat NJ, Sultana N, Haq MM, Rahman MM, Afrose M, Hossain MM, Alam MR. Effects of wet-to-dry bandages on second intention healing of surgical wounds on the skin of goats. *J Adv Vet Anim Res* 2020; 7(4):647–654.

Based on the physiology of wound healing, wounds are of two types, i.e., acute and chronic wounds [3]. External violence more commonly produces open wounds in the skin of ruminant species [4]. The management of wounds requires the cleansing of the wound bed with antiseptic solution [5], topical or parenteral administration of antibiotics [6], and protection of wounds by bandages against foreign bodies and microorganisms. Sometimes, saline washes may be used for a friendly atmosphere for asepsis. However, covering a wound with medicated non-stick gauze dressings absorbs wound exudates and fights against infection-producing microorganisms.

Wound healing is a complex process that typically undergoes restoration of tissue property, which means the cells, tissues, and parts of the body are restored to its usual form by the formation of connective tissues and reconstruction of the epithelium [7] and function [8,9]. Conceptually, the events of the wound healing process include inflammation, epithelialization, granulation, fibroplasia, and contraction [10]. Closing of the wound is essential in the second intention healing process. This process depends upon mitotic fibroblasts for the formation of granulation tissues that will contribute to growth by the movement of epithelial cells to the central point of the injury [11].

Numerous factors affect wound healing, many of which if interfered with might lead to improper or impaired tissue repair [12]. These factors have guided the progression of efficient therapeutic addresses to tissue repair, with minimization of the stimulating causes that delay or impair the healing process [13]. Skin grafting and biological dressings are developed to impede restricted damage to the tissues [14]. The external protection of the wound can be provided by several means, and one of the crucial devices is the dressing and bandaging. The importance of wet-to-dry bandages during the wound healing process in the skin has not been investigated as yet, especially in goats. In this regard, the current experimental study is designed to show the after effects of the wet-to-dry bandages, i.e., calcium alginate gel dressings, homogeneous platelet-rich plasma (PRP) gel dressings, and saline dressing on the skin wound healing process in goats. The effects of these dressings are also compared with each other.

## Materials and Method

### *Ethical approval*

The animal protocol used in the present study was reviewed and approved by the guidelines for taking care of animals

as accepted by the Animal Welfare and Experimentation Ethics Committee, Bangladesh Agricultural University, Mymensingh [AWEEC/BAU/2019(42)].

### *Animal models*

The present study was carried out at the Department of Surgery and Obstetrics, Bangladesh Agricultural University (BAU), Mymensingh. Twelve apparently healthy Black Bengal goats (age ranged from 1 to 1.5 years and body weight ranged from 12 to 15 kg) were procured for this experimental study. Based on the application of bandages, the experimental animals were divided into three groups, i.e., saline dressing, calcium alginate gel dressing, and PRP gel dressing in skin wound healing process. Each experimental group comprised four animals.

### *Surgical skin wounding*

A total of 48 skin wounds were made on the thigh muscles of all the experimental animals. The size of the created wounds was around 2.5 cm in length and 0.5 cm in depth. The experiment was conducted without using antibiotic, anti-allergic, or anti-inflammatory drugs. After the surgical operation, all necessary data were recorded from day 1 to 30 of the experiment. The morphological characteristics, i.e., swelling, exudations, and securization of the wound, were reported to reveal the healing process. The wound swelling was observed from days 0 to 3 of the operation. The length of wound contraction and the diameter of the wounds were measured on days 1, 3, 5, 7, 15, and 30 of operation. Additionally, the histopathological study was also carried out with physical characteristics.

### *Histopathological evaluation*

The skin wounds were collected from all groups on days 1, 3, 7, 15, and 30. They were removed, fixed in formalin, and then processed routinely for light microscopy. The fixed tissues were then dehydrated in ascending grades of alcohol and infiltrated in paraffin. Embedding of infiltrated samples was carried out using liquid paraffin and then prepared using tissue blocks. After hardening at room temperature, the tissue blocks were sectioned at 6  $\mu\text{m}$  (micrometer) in thickness using a microtome (sliding microtome, MIC 509, Euromex, Japan). Then, the sections were allowed to stretch by floating on a tissue floating bath (round tissue floatation bath, Medicus Health, Kentwood, MI) at 37°C. Mounting of the sections was carried out on glass slides using an adhesive (egg albumin) and then allowed to dry on a slide warmer at 37°C. Finally, the dried sections were stained with the routine stain, i.e., Mayer's Hematoxylin and Eosin (H&E), for microscopic study.

### Photomicrographs

The histopathology of the skin wounds was examined under a light microscope at two different magnifications (4X and 10X). Necessary photomicrographs were taken from the selected sections for the interpretation of the experimental outcome. Then, the photographs were evaluated by visual inspection to compare the effects of the applied dressings on surgically created skin wounds.

### Statistical analysis

All the data were analyzed by using the Statistical Package for the Social Sciences software version 19 (Chicago, IL). All the data were represented as mean  $\pm$  standard deviation (SD). The level of significance was expressed as \*\* =  $p < 1\%$  of significance, \* =  $p < 5\%$  of significance, and NS = not significant.

### Results

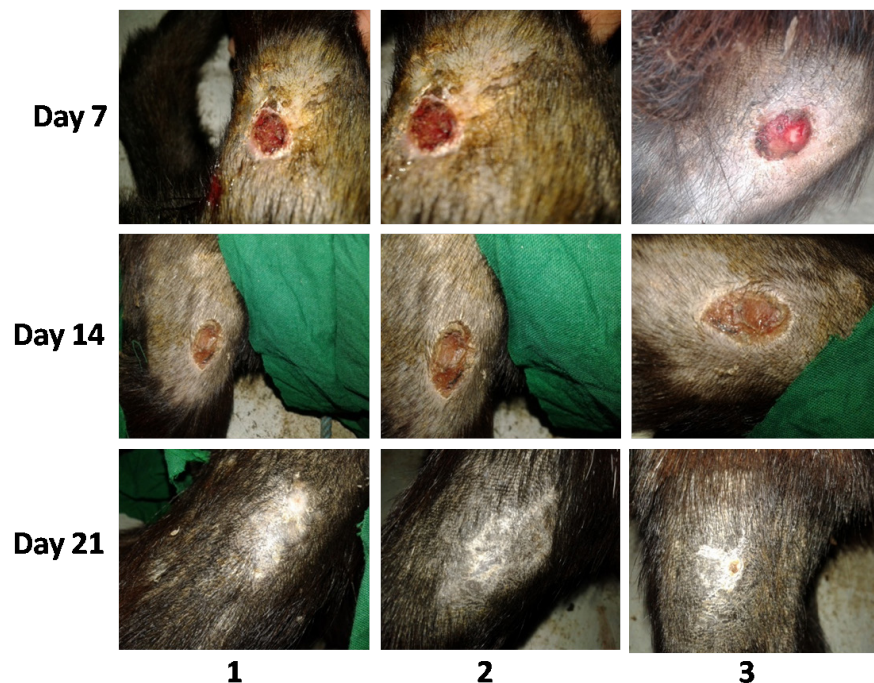
#### Morphological characteristics of skin wound during the healing process

The morphological characteristics of skin wound, i.e., duration of the healing process and contraction diameter

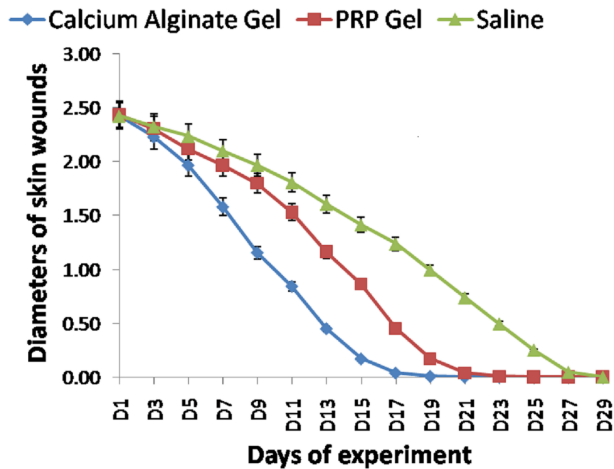
(cm) of the wound, were evaluated by the postoperative effects of three different types of treatments on the healing of the wound (Figs. 1 and 2). The contraction diameter of the wound was presented in three different treatments (Tables 1, 2, and 3). Based on the data derived, the effects of dry and wet dressings on the diameter of the wound show that the diameter of contraction of the wound was significantly higher in the calcium alginate gel treated group on days 3–27 and PRP gel treated group on days 5–27 in the wound area (Fig. 2). These experimental results, i.e., diameter of the wound, did not present any statistical inequality in wounds between calcium alginate gel and PRP gel treatments on day 1.

The healing score was excellent in both the wounds treated with calcium alginate gel dressing and PRP gel dressing as the wound area decreased more rapidly (Fig. 1). Prominent scar formation on the wound surface was seen in the control group (Fig. 1). No dehiscence was revealed in all the wounds of the goats in the experimental groups.

Based on the data of the healing score scale, calcium alginate gel dressing and homogenous PRP gel dressing showed excellent performance on the wound healing



**Figure 1.** Gross representation of surgical wounds closure treated by (1) calcium alginate gel dressing, (2) homogenous platelet-rich plasma gel dressing, and (3) saline dressing or control.



**Figure 2.** Graphical presentation of wound healing with calcium alginate gel, PRP gel, and saline dressing in Black Bengal goats.

**Table 1.** Effects of calcium alginate gel dressing on surgical wounds diameter (cm) (Mean  $\pm$  SEM) in goats.

Day	Mean $\pm$ SEM (cm)	p value	Day	Mean $\pm$ SEM (cm)	p value
D <sub>1</sub>	2.43 $\pm$ 0.031 <sup>NS</sup>	0.949	D <sub>17</sub>	0.04 $\pm$ 0.027**	0.0001
D <sub>3</sub>	2.2 $\pm$ 0.025*	0.061	D <sub>19</sub>	0.01 $\pm$ 0.006**	0.0001
D <sub>5</sub>	1.97 $\pm$ 0.024**	0.0001	D <sub>21</sub>	0.00 $\pm$ 0.000**	0.0001
D <sub>7</sub>	1.58 $\pm$ 0.045**	0.0001	D <sub>23</sub>	0.00 $\pm$ 0.000**	0.0001
D <sub>9</sub>	1.16 $\pm$ 0.034**	0.0001	D <sub>25</sub>	0.00 $\pm$ 0.000**	0.0001
D <sub>11</sub>	0.84 $\pm$ 0.052**	0.0001	D <sub>27</sub>	0.00 $\pm$ 0.000**	0.066
D <sub>13</sub>	0.45 $\pm$ 0.078**	0.0001	D <sub>29</sub>	0.00 $\pm$ 0.000 <sup>NS</sup>	–
D <sub>15</sub>	0.17 $\pm$ 0.049**	0.0001			

\*\* =  $p < 1\%$  of Significance, \* =  $p < 5\%$  of Significance, NS= Not Significant

process (Tables 1 and 2). But the healing score was good in the wound that was treated with saline dressing (Table 3).

### Histopathological assessments of the wound healing performance

The skin biopsies were collected from various kinds of wounds of the three treatment groups for histopathological analysis in the progression of repair of the wound healing process on days 1, 3, 7, 15, and 30. Histological evaluation of the wounds shows that the infiltration of numerous immunoreactive cells (macrophages, neutrophils, and lymphocytes) was observed under the keratin layers of the epidermis of wounds of calcium alginate gel and homogenous PRP gel on days 1, 3, and 7 (Fig. 3). On the contrary, fewer reactive cells were found in the control group after treatment (magnification 10 $\times$ ). Histopathological alterations in the progression of repair

**Table 2.** Effects of platelet-rich plasma gel dressing on surgical wounds diameter (cm) (Mean  $\pm$  SEM) in goats.

Day	Mean $\pm$ SEM (cm)	p value	Day	Mean $\pm$ SEM (cm)	p value
D <sub>1</sub>	2.44 $\pm$ 0.033 <sup>NS</sup>	0.949	D <sub>17</sub>	0.45 $\pm$ 0.078**	0.0001
D <sub>3</sub>	2.31 $\pm$ 0.030 <sup>NS</sup>	0.061	D <sub>19</sub>	0.17 $\pm$ 0.049**	0.0001
D <sub>5</sub>	2.12 $\pm$ 0.021**	0.0001	D <sub>21</sub>	0.04 $\pm$ 0.027**	0.0001
D <sub>7</sub>	1.97 $\pm$ 0.024**	0.0001	D <sub>23</sub>	0.01 $\pm$ 0.006**	0.0001
D <sub>9</sub>	1.80 $\pm$ 0.033**	0.0001	D <sub>25</sub>	0.00 $\pm$ 0.000**	0.0001
D <sub>11</sub>	1.53 $\pm$ 0.033**	0.0001	D <sub>27</sub>	0.00 $\pm$ 0.000**	0.066
D <sub>13</sub>	1.16 $\pm$ 0.038**	0.0001	D <sub>29</sub>	0.00 $\pm$ 0.000 <sup>NS</sup>	–
D <sub>15</sub>	0.86 $\pm$ 0.058**	0.0001			

NS = Not Significant.

\*\* =  $p < 1\%$  of significance; \* =  $p < 5\%$  of significance.

**Table 3.** Effects of saline dressing on surgical wounds diameter (cm) (Mean  $\pm$  SEM) in goats.

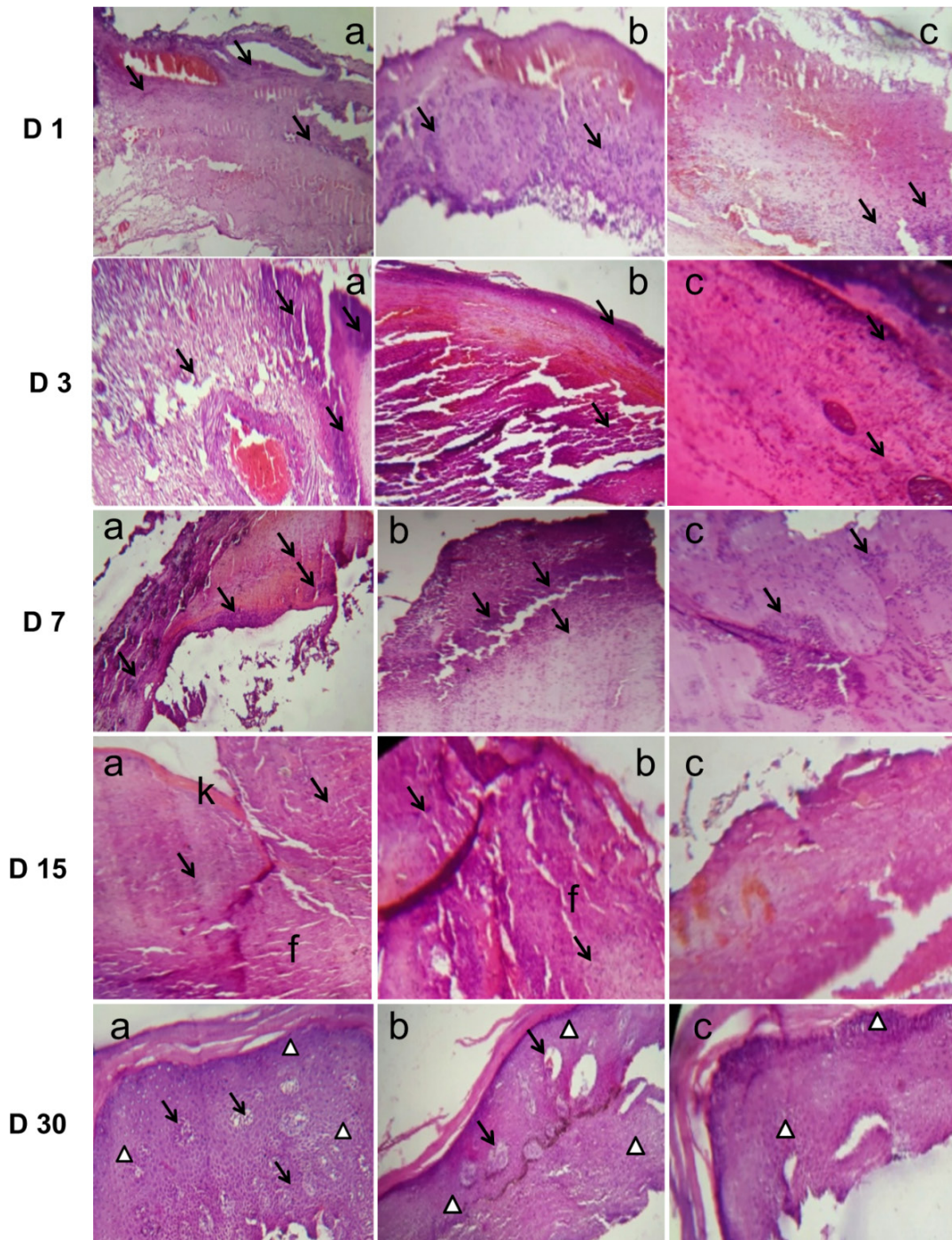
Day	Mean $\pm$ SEM (cm)	p value	Day	Mean $\pm$ SEM (cm)	p value
D <sub>1</sub>	2.43 $\pm$ 0.031 <sup>NS</sup>	0.949	D <sub>17</sub>	1.24 $\pm$ 0.053**	0.0001
D <sub>3</sub>	2.33 $\pm$ 0.031 <sup>NS</sup>	0.061	D <sub>19</sub>	0.99 $\pm$ 0.043**	0.0001
D <sub>5</sub>	2.24 $\pm$ 0.033**	0.0001	D <sub>21</sub>	0.74 $\pm$ 0.045**	0.0001
D <sub>7</sub>	2.10 $\pm$ 0.034**	0.0001	D <sub>23</sub>	0.49 $\pm$ 0.049**	0.0001
D <sub>9</sub>	1.97 $\pm$ 0.031**	0.0001	D <sub>25</sub>	0.25 $\pm$ 0.044**	0.0001
D <sub>11</sub>	1.81 $\pm$ 0.046**	0.0001	D <sub>27</sub>	0.04 $\pm$ 0.026 <sup>NS</sup>	0.066
D <sub>13</sub>	1.61 $\pm$ 0.062**	0.0001	D <sub>29</sub>	0.00 $\pm$ 0.000	–
D <sub>15</sub>	1.41 $\pm$ 0.054**	0.0001			

\* =  $p < 5\%$  of significance; \*\* =  $p < 1\%$  of significance.

NS = Not Significant.

of the wound healing process on day 15 are shown in Figure 3. On day 15, connective tissue with collagen fibers and full covering of epidermis with discrete inflammatory infiltration was observed in wounds treated with calcium alginate gel. Disruption of epithelial covering was found in wounds treated with homogenous PRP gel on day 15. The keratin layer of epithelial covering was irregularly disrupted in the wounds of the control group on D15 after treatment.

Histopathological changes in the progression of repair of the wound healing process on day 30 are shown in Figure 3. On day 30, complete healing was represented by more proliferating blood capillaries and inflammatory cells in the calcium alginate gel group. The homogenous PRP gel treated wounds showed the presence of a good number of blood vessels and inflammatory cells. Fewer blood capillaries and inflammatory cells were observed in the control groups in the wounds on D30. In the histopathological analysis, the presence of immunoreactive



**Figure 3.** Histopathological evaluations of wounds showing the progression of repair at day-1 (D1) and day-3 (D3), presence of numerous reactive cells (arrows) beneath the keratinized tissues of the epidermis of wounds of calcium alginate gel (a), presence of reactive cells beneath the keratinized tissues of the epidermis of wounds of homogenous PRP gel (b), and presence of few reactive cells at control groups after treatment (c). On day-7 (D7), newly formed connective tissue under the scab infiltrated with reactive cells (arrows) in wounds of calcium alginate gel (a), tissue reaction in wounds of homogenous PRP gel (b), and a huge number of reactive cells in wounds of control groups (c). On day-15 (D15), connective tissue with collagen fibers (f) between the cells and full covering of epidermis (k) with discrete inflammatory cells (arrows) in wounds of calcium alginate gel (a), disruption of epithelial covering in wounds of homogenous PRP gel (b), and irregular disrupted epithelial covering keratin layer in the wound of the control group (c). On day-30, stages of complete healing represented by the presence of numerous proliferating blood capillaries (arrows) and inflammatory cells (triangles) in calcium alginate gel group (a), presence of a good.

cells, accumulation of purulent discharges, reformation of epidermis, and propagation of connective tissue (fibrous) were recorded, which will help to learn the routine wound healing performance.

## Discussion

The skin is the biggest organ of an animal and human beings. Skin wound care has become a crucial concern accustomed to the progress of chronic wounds and its associated morbidity rates. To provide the best care for animals with wounds healing by secondary intention, it is crucial to explore good skin wound healing appliances. If a wound does not heal properly, it may advance into a chronic wound. This chronic wound may become a potential burden to the patient [15]. The current study design was aimed to detect the morphological and histopathological characteristics of a surgical wound treated with dry dressings, i.e., calcium alginate gel dressing, homogenous PRP gel dressing, and wet dressing, i.e., saline dressing, during the healing process. In this experimental study, the surgical skin wounds were observed for 30 days postoperative care, and some novel findings of the use of wet-to-dry bandages, i.e., calcium alginate gel, PRP gel, and saline dressings on the wound healing process in goat were established.

Alginate is a natural herbal copolymer [16]. It has a great water-absorbing trait, biodegradation, biocompatibility, excellent film-forming qualities, and capacity to entrap the bacteria that helps to fabricate the wound dressings [17]. Calcium alginate has outstanding cytocompatibility and histocompatibility characteristics. It acts as a booster of the wound healing process via elevating the contraction rate of wounds and modifying inflammatory reaction. It also increases the levels of type I collagen and hydroxyproline, leading to boost up the tensile strength of a wound [18]. Calcium alginate has stimulating effects on the expression of collagen type I and the rise of collagen type I to III ratios to a large area. This dressing affords a potential approach for healing of wounds [18].

On the other hand, PRP gel contains bioactive substances which enhance the healing process [19], and which contain an elevated level of platelets and an intrinsic level of fibrinogen [20,21]. In this study, it is shown that PRP topical application accelerates the rate of epidermal regeneration, increases wound tensile strength [22], and is useful in soft tissue healing.

Another parameter, wet dressing, allows healing for 24 h due to the wet condition of the wound [23]. This moisture-retentive dressing removes excess exudates [24]. Wet dressing promotes the excellent function of cells and

proteases and stimulates rapid closing of the wound with a lesser degree of infection [25]. There is lesser shifting of the bandage during and in between change, which is more adjustable [25]. Overall, wet dressing decreases the costs for total wound care. The wet dressing does not desiccate the wound bed. When the dry dressing is removed, essential cells and tissue, granulation tissues, and regrown epithelial cells and WBCs, as well as dead tissues are not developed which is the main problem with dry dressing. So, wet dressing revealed an excellent healing score with no postoperative adverse effects in the current research work.

If the wound takes more than 12 weeks to heal, then it might be associated with metabolic disorders [13]. In this experimental study, the wounds were rapidly closed in 21 days, both in the calcium alginate gel treated group and PRP gel dressed group when compared to that of the control groups.

In this experimental study, the contraction diameter of the wound was statistically higher in both the calcium alginate gel treated group and the PRP gel treated group. The contraction diameter, i.e., centripetal or concentric reduction, of an open wound is a prerequisite for the secondary intention healing of that wound that is produced by the migration of fibroblasts to granulation tissue on the skin margins. Usually, a wound contraction can conclude in a periodic complete wound closure; however, any irregularities in contraction may result in the partial closure of the wound [26]. The current result suggests a good to excellent wound closure with calcium alginate gel and PRP gel dressings.

The subsequent incursion of immunoreactive cells, i.e., neutrophils, macrophages, and lymphocytes, was observed in the inflammatory site, which is histopathologically examined by another group of researchers [27–29].

Histological evaluations of the wound showed the access of immunoreactive cells, accretion of purulent discharges, reformation of the epidermis, and augmentation of connective tissue, i.e., fibrous, among the cells of the wounds treated with calcium alginate gel dressing and PRP gel dressing. This result is in line with human studies carried out by previous research [29].

The present surgical experimental study found that the diameter of the wounds treated by dry bandages (calcium alginate gel dressing and PRP gel dressing) were reduced significantly compared to the control group (wet dressings). Applications of dry dressings, i.e., calcium alginate gel and homogenous PRP gel on wound healing, are excellent than wet dressing. The characteristic of tissue destruction (calcium alginate gel) is almost similar in both calcium alginate gel dressing and PRP gel dressing.

## Conclusion

The present study concludes that the wet dressing has a better beneficial effect on surgical wound healing. In addition to this, calcium alginate gel and homogenous PRP gel also showed good results on the wound healing process. The effects of the two gels are more or less similar. But, calcium alginate is a synthetic product which causes some side effects. On the other hand, PRP gel is a bioactive substance having no side effects. Therefore, the role of wet dressing is better in wound healing when compared to dry dressing. The present research study could help veterinary practitioners to consider the use of biomaterial substance in soft tissue healing and wet dressing for the wound healing in the skin of goats.

## Acknowledgments

The authors acknowledge the Department of Surgery and Obstetrics and Department of Anatomy and Histology, Faculty of Veterinary Science, Bangladesh Agricultural University (BAU), Bangladesh, for research assistance and technical support.

## Conflict of interest

There is no conflict of interest among the authors regarding the publication of this article.

## Authors' contribution

MMR and MMH conceptualized and designed the experimental study. MR and MRA supervised the experimental study. NJZ and MMH carried out the experiment and laboratory work. NS and MA interpreted the results and drafted the manuscript.

## References

- [1] Kordestani SK. Atlas of wound healing: a tissue generation approach. 1st edition, Elsevier, Amsterdam, Netherlands, 2019; <https://doi.org/10.1016/B978-0-323-67968-8.00003-3>
- [2] Jones H, Peskar BM, Levin E, Itani RM, Sarfeh IJ. Inhibition of angiogenesis by non steroidal anti-inflammatory drugs: insight into mechanisms and implications for cancer growth and ulcer healing. *Nat Med* 2003; 5:1418–23; <https://doi.org/10.1038/70995>
- [3] Kumar B, Vinaykumar M, Govindarajan R, Pushpangadan P. Ethanopharmacological approaches to wound healing exploring medicinal plants of India. *J Ethanopharmacology* 2007; 114:103–13; <https://doi.org/10.1016/j.jep.2007.08.010>
- [4] Arju MT, Samaddar K, Rahman MM, Haq MM, Rana MS, Juyena NS, et al. Surgical affections: a comparative scenario of chittagong region, *Int J Nat Soc Sci* 2014; 1:37–44.
- [5] Drosou A, Falabella A, Robert S. Antiseptics on wounds: an area of controversy. *Wounds* 2003; 15:6; <https://www.woundsresearch.com/article/1585>
- [6] Singhal H. Wound Infection Medication. 2017. Available via <http://emedicine.medscape.com/article/188988-medication>
- [7] Mohammedaman M, Teshome T, Detamo J. Antibacterial activity of honey against methicillin-resistant staphylococcus aureus: a laboratory-based experimental study. *Int J Microbiol* 2019; 3:7686130; <https://doi.org/10.1155/2019/7686130>
- [8] AlMatar M, Batoool T, Makky EA. Therapeutic potential of N-acetylcysteine for wound healing, acute bronchiolitis, and congenital heart defects. *Curr Drug Metab* 2016; 17(2):156–67; <https://doi.org/10.2174/1389200217666151210124713>
- [9] Mercandetti M. Wound healing and repair. 2017; Available via <http://emedicine.medscape.com/article/1298129-overview>
- [10] Mathieu D, Linke JC, Witten TM, Wattel F. Non-healing wounds. In: Mathieu DE (ed.). *Handbook on hyperbaric medicine*. Springer, Dordrecht, Netherlands, pp 401–27, 2006; [https://doi.org/10.1007/1-4020-4448-8\\_20](https://doi.org/10.1007/1-4020-4448-8_20)
- [11] Tillmann MT, Felix AOC, Mueller EN, Felix SR, Alves GH, Ramos TS, et al. Use of triticum aestivum in open wound healing: a clinical, pathological, and tensiometric assessment in the rabbit model. *Arq Bras Med Vet Zootec* 2014; 66(6):1757–61; <https://doi.org/10.1590/1678-7132>
- [12] Guo S, DiPietro LA. Factors affecting wound healing. *J Dent Res* 2010; 89(3):219–29; <https://doi.org/10.1177/0022034509359125>
- [13] Sarheed O, Ahmed A, Shouqair D, Boateng J. Antimicrobial dressings for improving wound healing. *IntechOpen Limited*, London, UK, pp 373–94, 2016; <https://doi.org/10.5772/63961>
- [14] Fatima S, Siddiqui SR, Alamer NA, Monga HS, Srivastava M. Role of amniotic membrane in oral and maxillofacial surgery. *Eur J Biomed Pharm Sci* 2016; 3:149–52.
- [15] Han G, Ceilley R. Chronic wound healing: a review of current management and treatments. *Adv Ther* 2017; 34:599–610; <https://doi.org/10.1007/s12325-017-0478-y>
- [16] Jayakumar R, Rajkumar M, Freitas H, Selvamurugan N, Nair SV, Furuie T, et al. Preparation, characterization, bioactive and metal uptake studies of alginate/phosphorylated chitin blend films. *Int J Biol Macromol* 2009; 44:107–11; <https://doi.org/10.1016/j.ijbiomac.2008.10.010>
- [17] Lazaro-Martinez JL, Cecilia-Matilla A, Aragon-Sanchez J, Garcia-Morales E, Garcia-Alvarez Y, Alvaro-Afonso F. Treatment of infected diabetic foot ulcers clinical effectiveness of a dressing of alginate and hydrocolloid, with silver fiber. Analysis of results of a series of cases. *Rev Enferm* 2013; 36:29–34; <https://www.ncbi.nlm.nih.gov/pubmed/24404714>
- [18] Wang T, Qisheng G, Zhao J, Mei J, Shao M, Pan Y, et al. Calcium alginate enhances wound healing by up-regulating the ratio of collagen types I/III in diabetic rats. *Int J Clin Exp Pathol* 2015; 8:6636–45.
- [19] Albanese A, Licata ME, Polizzi B, Campisi G. Platelet-rich plasma (PRP) in dental and oral surgery: from the wound healing to bone regeneration. *Immun Ageing*. 2013; 10: 23; <https://doi.org/10.1186/1742-4933-10-23>
- [20] Carlson NE, Roach RB. Platelet-rich plasma: clinical applications in dentistry. *J Am Dent Assoc*. 2002; 10:1383–6; <https://doi.org/10.14219/jada.archive.2002.0054>
- [21] Kao RT, Murakami S, Beirne OR. The use of biologic mediators and tissue engineering in dentistry. *Periodontol* 2009; 10:127–53; <https://doi.org/10.1111/j.1600-0757.2008.00287.x>
- [22] Wesner M, Defreitas T, Bredy H, Pothier L, Qin Z, McKillop AB, et al. A pilot study evaluating the effectiveness of platelet-rich plasma therapy for treating degenerative tendinopathies: a randomized control trial with synchronous observational cohort. *PLoS One* 2016; 11:2; <https://doi.org/10.1371/journal.pone.0147842>
- [23] Mayet N, Choonara YE, Kumar P. A comprehensive review of advanced biopolymeric wound healing systems. *J Pharm Sci* 2014; 103:2211–30; <https://doi.org/10.1002/jps.24068>
- [24] Junker JPE, Kamel RA, Caterson EJ, Eriksson E. Clinical impact upon wound healing and inflammation in moist, wet, and dry environments. *Adv Skin Wound Care* 2013; 2:348–35; <https://doi.org/10.1089/wound.2012.0412>

- [25] Dissemond J, Augustin M, Eming SA. Modern wound care—practical aspects of non-interventional topical treatment of patients with chronic wounds. *J Dtsch Dermatol Ges* 2014; 12:541–53; <https://doi.org/10.1111/ddg.12351>
- [26] Swaim SF, Hinkle SH, Bradley DM. Wound contraction: basic and clinical factors. *Compend Contin Educ Pract Vet N Am Ed* 2001; 23(1):20–33.
- [27] Gosain A, Dipietro LA. Aging and wound healing. *World J Surg* 2004; 28:321–6; <https://doi.org/10.1007/s00268-003-7397-6>
- [28] Broughton G, Janis JE, Attinger CE. The basic science of wound healing. *Plast Reconstr Surg* 2006; 117:12–34; <https://doi.org/10.1097/01.prs.0000225430.42531.c2>
- [29] Campos AC, Groth AK, Branco AB. Assessment and nutritional aspects of wound healing. *Curr Opin Clin Nutr Metab Care* 2008; 11:281–8; <https://doi.org/10.1097/MCO.0b013e3282fbd35a>