

ORIGINAL ARTICLE

Characterization and assessment of naturally mutant non-pathogenic O27 strain *Escherichia coli* and their potential use as poultry probiotics

Nabila Osman¹, Shimaa A. M. Ahmed², Dina M. W. Shibab El-hamd², Ahmed I. Ahmed¹

¹Department of Poultry Diseases, Faculty of Veterinary Medicine, South Valley University, Qena, Egypt

²Department of Poultry Diseases, Agricultural Research Center ARC, Animal Health Research Institute, Qena, Egypt

ABSTRACT

Objective: The purpose of the current study was to evaluate the molecular characteristics of naturally mutant non-pathogenic O27 strain of *Escherichia coli* and its efficacy as probiotic in broilers and determine the best age at which it can be administered.

Materials and methods: A total of 24 virulence genes using 24 sets of primers were detected using the polymerase chain reaction technique. For probiotics experiments, 60 chicks (day 1 old) were divided into three groups, 20 per group, and reared for 4 weeks. The first group was considered as a negative control. The second group was treated orally with O27 strain at first day of life for three successive days and repeated at day 21. The third group was administered orally with O27 strain at day 10 old, and repeated at day 21 old.

Results: The data revealed that type 1 fimbrial adhesion, salmochelin siderophore receptor, and sigma factor-binding protein were detected in O27 strain, but temperature-sensitive hemagglutinin, hemolysin secretion gene, pyelonephritis-associated Pili gene, polysaccharide capsule synthesis gene, Shiga-toxin1 gene, Shiga-toxin2 gene, Brain microvascular endothelial cell invasion, *E. coli* attaching and effacing gene, heat-stable enterotoxin, heat-labile enterotoxin, east 1 toxin, colicin V, verotoxin type 2, necrotizing cytotoxic factor type 1, colonization factor antigen I, colonization factor antigen III, coli surface 2, coli surface 4, serine protease pic autransporter, vacuolating autransporter toxin, and serine protease EspP precursor were not detected in O27 strain. Group 2 performance parameters were significantly better ($p < 0.01$) than groups 3 and 1. Hematological and biochemical parameters did not be influenced ($p > 0.05$) by the administration of O27 strain. Antibody titers of infectious bursal disease virus and Newcastle disease virus in groups 2 and 3 were improved as compared to group 1. Group 2 had significantly higher titers than group 3. Histopathologically, all groups showed normal histopathological pictures. However, jejunum in groups 2 and 3 showed more tall, intact, and densely packed microvilli and more crypt depth than the control group.

Conclusion: The O27 strain of *E. coli* is non-pathogenic bacteria. Its effects on growth performances and enhancement of immunity in broilers match with the same impact of probiotics, and these candidates will fit to be a good probiotic in the future. The results revealed that the effects of O27 strain at the day 1 old of life for three successive days and repeated at day 21 old are better for improving the performance and immunity of the birds. More research works about the characterized non-pathogenic *E. coli* strain O27 are required for field and commercial use.

ARTICLE HISTORY

Received April 24, 2020
Revised May 20, 2020
Accepted May 20, 2020
Published June 29, 2020

KEYWORDS

E. coli O27 strain; probiotic; virulence genes; histopathology



This is an Open Access article distributed under the terms of the Creative Commons Attribution 4.0 Licence (<http://creativecommons.org/licenses/by/4.0>)

Introduction

In many countries, the poultry industry has become an essential economic activity. In large-scale rearing facilities, where poultry is subjected to stressful conditions, disease-related problems and environmental deterioration

often occur and result in significant financial losses. For many decades, antibiotics were used not only as a way of controlling infectious diseases but also for enhancing growth performance and feed efficiency [1]. However, despite extensive documentation on the evolution of

Correspondence Ahmed I. Ahmed ✉ ibrahim.ahmed25@yahoo.com 📧 Department of Poultry Diseases, Faculty of Veterinary Medicine, South Valley University, Qena, Egypt.

How to cite: Osman N, Ahmed SAM, El-Hamd DMWS, Ahmed AI. Characterization and assessment of naturally mutant non-pathogenic O27 strain *Escherichia coli* and their potential use as poultry probiotics. J Adv Vet Anim Res 2020; 7(3):374–383.

antimicrobial resistance among pathogenic bacteria, the utility of antimicrobial agents as a preventive measure has been questioned. Hence, the possibility of the antibiotic as a growth stimulant ceasing to be used for poultry and the concern about the side effects of its use as a therapeutic agent has created an environment in which consumers and manufacturers are searching for alternatives. Probiotics are considered to fill this gap, and some farmers already use them, preferably to antibiotics [2–4].

Probiotics are living microorganisms that enter actively into the gastrointestinal tract (GIT) and exert a positive influence on the host tissues [5]. Mach [6] concluded that probiotics were potentially a feasible alternative to antimicrobial growth promoters in broiler feeding, orally administered and beneficial to host health by inhibiting pathogens, improving immunity, and having a protective impact on intestinal microflora. Recent research has indicated probiotics' possible therapeutic role in the prevention or treatment [7–10].

Lactobacillus bulgaricus, *Enterococcus faecium*, *L. plantarum*, *Escherichia coli*, *Bifidobacterium* species, *E. faecalis*, and *Streptococcus thermophilus* can be used in probiotic preparations [11]. It is believed that the microorganisms used as probiotics are non-pathogenic components of the normal microflora, such as the lactic acid bacteria. The non-pathogenic variants of pathogenic species can act in the same way as traditional probiotics do as avirulent mutants of *Clostridium difficile*, *E. coli*, and *Salmonella typhimurium* [12].

The naturally mutant non-pathogenic O27 strain was isolated from a liver sample of a healthy 7-day-old chick reared in commercial broiler chicken farm in Qena Governorate, Egypt, which could be an interesting candidate for a probiotic to prevent the bacterial diseases in poultry intestine and to improve growth performance and immunity of poultry [13]. The current study is intended to study the molecular genetic characteristics of naturally mutant non-pathogenic *E. coli* O27 strain by using polymerase chain reaction (PCR) and to study the pathogenicity, the age at which the naturally mutant non-pathogenic O27 strain of *E. coli* as a probiotic can be administered, and its effects on growth performance, induction of chicken antibody response, hematological and biochemical parameters, and histopathological studies.

Materials and Methods

Ethical approval

The Research Ethics Committee of the Faculty of Veterinary Medicine, University of South Valley, Egypt, has given ethical approval (approval number: Directive 2018/13/VET-SVU). All procedures performed involving poultry

during the current study were following the institutional guideline, which follows the international and national guidelines.

Detection of virulence genes in *E. coli* O27 strain

The PCR-technique was implemented with 24 sets of primers to detect 24 virulence genes. The genes were type 1 fimbrial adhesion (*fimH*), salmochelinsiderophore receptor (*iroN*), sigma factor-binding protein (*crl*), temperature-sensitive hemagglutinin (*tsh*), hemolysin secretion gene (*hly*), pyelonephritis-associated Pili gene (*papC*), polysaccharide capsule synthesis gene (*kpsMTII*), shigatoxin 1 (*stx1*), shigatoxin 2 (*stx2*), brain microvascular endothelial cell invasion (*ibeA*), *E. coli* attaching and effacing gene (*eaeA*), heat-stable enterotoxin (*STa*), heat-labile enterotoxin (*LT*), east 1 toxin (*astA*), colicin V (*cvaC*), verotoxin type 2 (*VT2e*), necrotizing cytotoxic factor type 1 (*cnf1*), colonization factor antigen I (*cfaI*), colonization factor antigen III (*cfaIII*), coli surface 2 (*CS2*), coli surface 4 (*CS4*), serine protease Pic autransporter (*pic*), vacuolating autotransporter toxin (*vat*), and serine protease EspP precursor (*espP*) genes. PCR was applied by following QIAamp DNA Mini Kit instructions (Catalogue no. 51304) and EmeraldAmp GT PCR Master Mix (Takara) Code No. RR310A [14]. The positive PCR products for each gene were detected and visualized in single 1.5% agarose gel electrophoreses stained with ethidium bromide, viewed by the UV light.

Studying the pathogenicity, the age at which the naturally mutant non-pathogenic O27 strain of *E. coli* as a probiotic can be administered, and its effects on growth performance, induction of chicken antibody response, hematological and biochemical parameters, and histopathological studies

Experimental birds

Sixty-five broiler chicks (day 1 old) (Ross) were picked from a commercial hatchery. Five chicks (day 1 old) were sacrificed randomly on the first day, and samples from the liver, kidney, yolk swabs, pericardium, and air sacs were examined bacteriologically for pathogenic *E. coli*. All the results were *E. coli* negative. The remaining 60 chicks were assumed *E. coli* free, weighed individually, randomly assigned to three groups, and separately kept in a suitable environment at experimental units (Animal Health Research Institute, Qena, Egypt).

The broilers were reared for 4 weeks. The chicks of all groups were fed freely with age-appropriate commercial diets without the addition of antibacterial or anticoccidial components, before and through the experiments, and kept under daily observation of all groups with recording clinical signs and/or mortality, postmortem lesions.

The experimental birds were vaccinated with Hitchner and colon strain of Newcastle disease virus (NDV) on day 6 and day 18 through intraocular route, respectively, and also were immunized with an intermediate strain of infectious bursal disease virus (IBDV) through intraocular route on days 12 and 24 of age, respectively.

Experimental design

Each group containing 20 chicks was distributed in the following manner:

The first group was a negative control, fed a basal diet only. The second group was orally administered 6×10^8 Colony Forming Unit (CFU) viable organism/ml naturally mutant non-pathogenic O27 strain at the first day of life for three successive days and repeated at day 21 old. The third group was orally administered 6×10^8 CFU viable organism/ml naturally mutant non-pathogenic O27 strain of *E. coli* at day 10 old for three successive days and repeated at day 21 old.

Growth performance and nutrient utilization

Weights were taken on the first day and every week. Weekly feed consumption/grams were calculated every week until the fourth week. Feed conversion ratio (FCR) was obtained as the feed consumption per kg body weight (BW) gain. Performance index (PI) was obtained for each experimental diet as a ratio of average BW gain and FCR.

Hematological and biochemical analyses

At the last day of the experiment, five birds per group were slaughtered:

Whole blood was collected in a sterile ethylenediaminetetraacetic acid (EDTA) container for the estimation of differential leukocyte count (DLC) by using the standard two-slide wedge technique as in mammalian blood according to the previous studies [15–17].

Serum was analyzed for total protein by using the spectrophotometric technique (biuret method), according to Caprita et al. [18] and albumin by using the dye-binding technology, according to Gustafsson [19]. Globulins (G) were obtained through the subtraction of albumin (A) from total serum proteins, according to Ross et al. [20].

Assessment of immune response

Hemagglutination inhibition (HI) test was used to measure antibody titers to live NDV vaccine using Lasota Ag of NDV, which was prepared by reference laboratory for quality control on poultry production. In contrast, the enzyme-linked immunosorbent assay (ELISA) test was used to measure antibody titers to IBDV vaccine by using BioChek Poultry Immunoassays, an infectious bursal disease antibody test kit, Catalogue Code CK113. On the last day of the experiment, five birds per each group were selected randomly, and 5 ml of whole blood were collected from the wing vein of these birds

in tubes. Whole blood was allowed to clot overnight at 4°C and then centrifuged at $3,000 \times gm$ for 10 min. The separated sera were stored at $-20^\circ C$ till used in the serological tests.

Histopathological picture

Organ tissues (duodenum, jejunum, and cecum) which were collected aseptically for P/M examination were fixed in 10% formalin then washed with varying concentrations of alcohol and embedded in paraffin. Embedding cups containing organ tissue were filled with liquid paraffin and left to solidify on ice, after which the block was carefully removed to make 1–3- μm sections using a microtome. Hemotoxylin–eosin and toluidine blue staining were carried out according to the standard protocols.

Statistical analysis

The experimental data were subjected to statistical analysis using SPSS software by a completely randomized design employing a one-way analysis of variance according to Field [21] and the Chi-square test, according to Pearson [22]. The significant differences were taken at $p < 0.05$.

Results

Polymerase chain reaction

PCR results shown in Figure 1 revealed that *fimH*, *iroN*, and *crl* genes were detected in O27 strain, but *tsh*, *hly*, *papC*, *kpsMTII*, *stx1*, *stx2*, *ibeA*, *eaeA*, *STa*, *LT*, *astA*, *cvaC*, *VT2e*, *cnf1*, *cfaI*, *cfaIII*, *CS2*, *CS4*, *pic*, *vat*, and *espP* were not detected in O27 strain.

Clinical signs and postmortem lesions

All birds of the three groups appeared healthy, full vitality, and activity with no post-mortem (PM) lesions, as shown in Figure 2.

Mortality rate

There was no mortality along the period of the experiment in all the groups.

Growth performances and nutrient utilization

Mean BW, feed consumption, and PI are shown in Table 1. Significantly ($p < 0.01$) higher performance parameters, BW, weekly feed consumption/grams, and PI were recorded in broilers of groups 2 and 3 compared to the control group (group 1). Group 2 showed significantly higher performance parameters than group 3.

Hematological findings

O27 strain of *E. coli* supplementation did not influence ($p > 0.05$) the DLC in two groups (groups 2 and 3), and also group 1 exhibits normal hematological parameters, as shown in Table 2.




Figure 1. PCR products of amplified of virulent genes identified in the O27 strain of *E. coli* visualized on agarose gel electrophoresis. The expected molecular size of amplified DNA: 508 bp for *fimH* gene (A), 847 bp for *iroN* gene (B), 250 bp for *crl* gene (C), 620 bp for *tsh* gene (D), 1177 bp for *hly* gene (E), 501 bp for *papC* gene (F), 280 bp for *kpsMTII* gene (G), 614 bp for *stx1* gene (H), 779 bp for *stx2* gene (I), 342 bp for *ibeA* gene (J), 248 bp for *eaeA* gene (K), 229 bp for *STa* gene (L), 606 bp for *LT* gene (M), 110 bp for *astA* gene (N), 760 bp for *cvaC* gene (O), 322 bp for *VT2e* gene (P), 620 bp for *cnf1* gene (Q), 364 bp for *cfal* gene (R), 437 bp for *cfalIII* gene (S), 368 bp for *CS2* gene (T), 250 bp for *CS4* gene (U), 572 bp for *pic* gene (V), 420 bp for *vat* gene (W), and 547 bp for *espP* gene (X), Lane PC: Positive Control, Lane NC: Negative Control, Lane S: samples, and Lane (L) DNA ladder 100 bp.

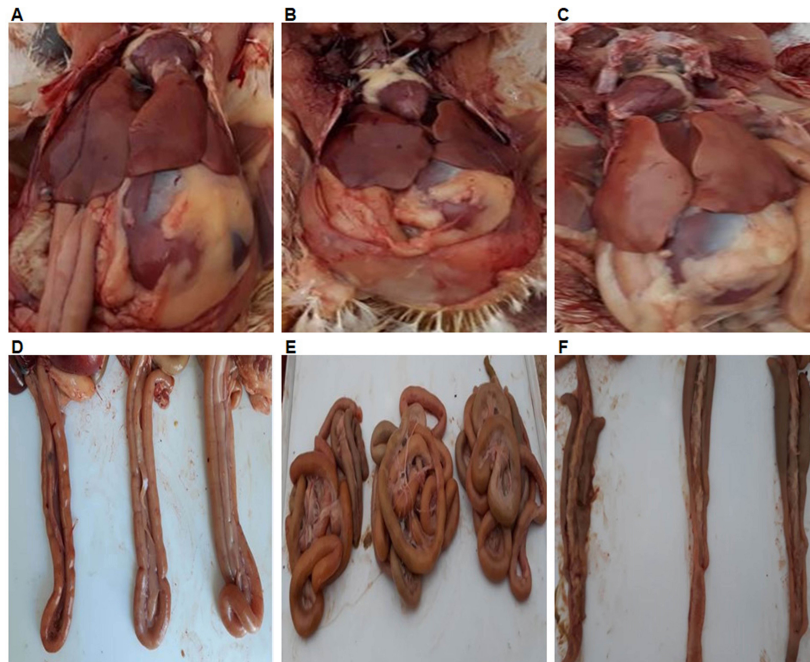


Figure 2. Post-mortem (PM) results of 28-day-old chickens from group 1 (A), group 2 (B), and group 3 (C), all of them showing healthy liver and heart. (D) 28-day-old chickens from group 1 on the left, group 2 in the middle, and group 3 on the right, all of them showing normal duodenum. (E) 28-day-old chickens from group 1 on the left, group 2 in the middle, and group 3 on the right, all of them showing normal jejunum. (F) 28-day-old chickens from group 1 on the left, group 2 in the middle, and group 3 on the right, all of them showing normal cecum.

Table 1. Effect of the naturally mutant non- pathogenic O27 strain of *E. coli* supplementation on growth performances of broiler chickens.

Groups	Age/week	Mean weekly BW/gm	Weekly feed consumption/gm	PI
Group 1	First	143	800	286
Group 2		152.7	900	305.4
Group 3		143	800	286
Chi-Square		0.42895	8.43687	0.8579
Significance		Non	0.05	Non
Group 1	Second	374.5	3,725	340.4
Group 2		432	4,500	392.7
Group 3		382	3,925	347.2
Chi-Square		4.93269	79.9383	4.49114
Significance		Non	0.01	Non
Group 1	Third	669.3	7,000	446.2
Group 2		842.7	9,000	601.9
Group 3		750.3	8,000	577.1
Chi-Square		19.9648	250	25.8383
Significance		0.01	0.01	0.01
Group 1	Fourth	1,000	10,000	769.2
Group 2		1,289	11,000	991.5
Group 3		1,229	10,500	945.3
Chi-Square		39.6708	47.619	30.5111
Significance		0.01	0.01	0.01

Table 2. Differential leucocyte count for 3 groups ($n = 100$ cells).

Groups	Type of cells					
	Heterophils	Esinophils	Basophils	Lymphocytes	Monocytes	Thrombocytes
Group 1	20	3	1	69	5	2
Group 2	26	2	2	60	7	3
Group 3	25	3	1	63	6	2
Chi-Square	0.87324	0.25	0.5	0.65625	0.33333	0.28571
Significance	Non	Non	Non	Non	Non	Non

Table 3. Effects of *E. coli* O27 strain supplementation on different blood biochemical parameters in broiler chickens.

Groups	Biochemical parameters		
	Total protein	Albumin	Globulin
Group (1)	2.85	1.45	1.4
Group (2)	3.13	1.56	1.57
Group (3)	2.9	1.45	1.45
F	2.55	2.8	2.33
Significance	Non	Non	Non

Biochemical findings

As shown in Table 3, there were normal biochemical parameters with no significant ($p > 0.05$) difference in all groups.

Immune response

As shown in Table 4, the supplementation of O27 strain in groups 2 and 3 increased the antibody titers against Newcastle disease (ND) and infectious bursal disease (IBD) comparing to untreated control (group 1). The birds in group 2 had significantly ($p < 0.01$ and $p < 0.05$) higher titers against ND and IBD, respectively, than those in group 3.

Histopathological finding

Normal histopathological pictures were in all birds of the three groups, but the longer, intact, and densely packed microvilli and more crypt depth in the jejunum of groups 2 and 3 compared to the control group 1 as shown in Figure 3.

Discussion

The current article studied the genetic characteristics of the O27 strain of *E. coli* and its relation to virulence because the probiotic must be avirulent. *fimH* gene was detected in O27 strain, and this finding agreed with Lasaro et al. [23], who mentioned that *fimH* was also detected in EcN (*E. coli* strain Nissle 1917) which is a probiotic of *E. coli* origin. This finding was explained by Sonnenborn and

Table 4. Immune response (HI antibody titer) to NDV vaccine and (ELISA antibody titer) to a vaccine strain of IBD virus in broiler chickens as influenced by *E. coli* O27 strain supplementation.

Groups	Mean antibody titer	
	ND HI	IBD ELISA
Group (1)	2.33	218
Group (2)	4	717.75
Group (3)	2.5	555.67
F	10.99	4.79
Significance	0.01	0.05

Schulze [24]. They mentioned that *fimH* facilitates adhesion to intestinal epithelial cells in cell culture *in vitro* experiments or to the mucus layer of the intestinal wall *in vivo*, facilitating colonization of the gut.

iroN gene was detected in O27 strain, and this finding agreed with Sonnenborn and Schulze [24], who found that *iroN* was also detected in EcN. *iroN* which is one of siderophores that are iron-chelating substances needed for bacterial iron uptake [25]. Iron is an essential element for *E. coli* survival. It facilitates numerous cellular activities, such as reducing peroxide, transporting electrons, and biosynthesizing nucleotides [26,27].

crl (sigma factor-binding protein) gene was detected in O27 strain, this gene is required for normal stationary phase during stress conditions, and this result agreed with Lelong et al. [28], who mentioned that *crl* gene was previously believed to encode the significant curlin subunit of curli (curli are surface structures that are induced by growth at stationary phase during stress conditions as low osmolarity and low temperature). It was later established that *crl* makes a positive contribution to stimulating the transcription of *csgBA*, the true locus encoding for the main subunit of curli. The standard stationary-phase induction of *csgBA* requires RpoS as well. Based on these results, the presence of three previous genes strengthens its effects as a probiotic through mediating its colonization of the gut, increasing its ability to iron uptake needed for its cellular activities, and surviving during stationary phase under stress conditions.

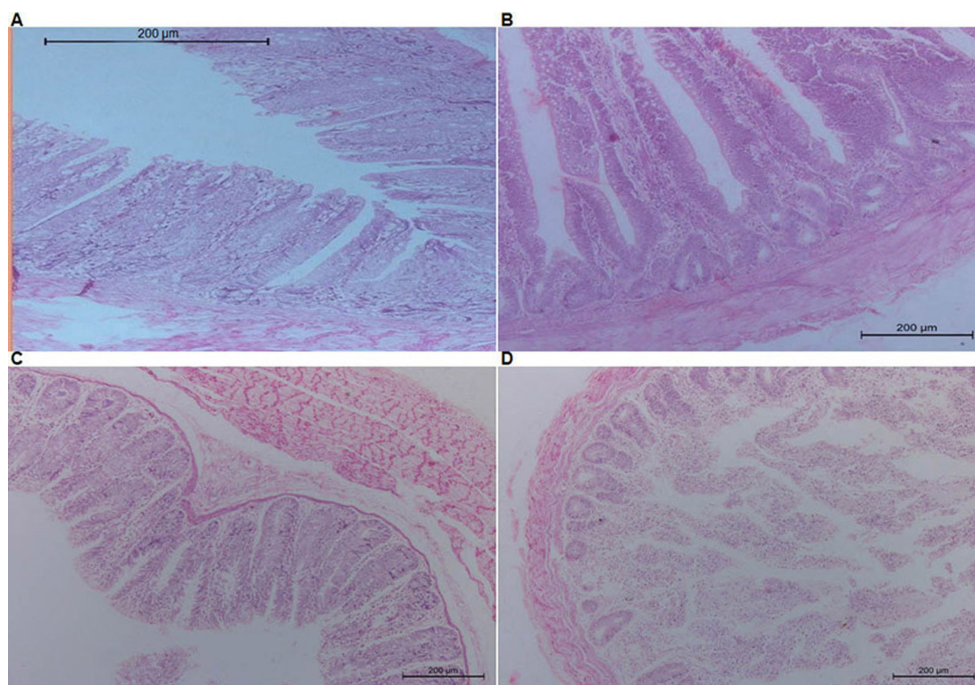


Figure 3. Jejunal sections from 28 day old chicken showing normal villi and normal active glands in both pictures with more intact and densely packed microvilli in group (2) (A) than group (1) (B). (C) Cecal section from 28 day old chicken showing normal cecal glands and villi, all of the 3 groups showing the same picture. (D) Deudenal section from 28 day old chicken showing normal villi and normal deudenal gland, all of the 3 groups showing the same picture.

hly, *papC*, *stx1*, *stx2*, *STa*, *LT*, *cfal*, *cfalIII*, *CS2*, and *CS4* virulence genes were not detected in O27 strain, and this result agreed with Sonnenborn and Schulze [24], who mentioned that these genes were not identified in EcN. The obtained data refer to the high similarity between O27 and EcN strains, which is a probiotic of *E. coli* origin and supports the idea of being O27 a probiotic.

kpsMTII was not detected in O27 strain, and this finding agreed with Miajlovic et al. [29] who mentioned that, in many extraintestinal pathogenic *E. coli* (ExPEC) strains, the existence of a capsule protects the pathogen from attacks by non-specific blood serum defense components (e.g., complement), thus making the serum resistant to bacteria. Serum resistance expanded the bloodstream's survival time and increases a pathogen's virulence. In light of the above, the O27 strain is serumsensitive and is rapidly destroyed in the presence of human serum or sera of other mammalian species. In the case of comparing this finding with EcN, this finding disagreed with Sonnenborn and Schulze [24], who mentioned that *kpsMTII* was detected in EcN, but interestingly it is serumsensitive.

tsh, *ibeA*, *astA*, *cvaC*, *VT2e*, *cnf1*, *picespP*, and *vat* were not detected in O27 strain, and these results agreed with Compos et al. [30], who proved that the *tsh* gene was found

among chickens-isolated avian pathogenic *Escherichia coli* (APEC) strains, and also agreed with Germon et al. [31], who stated that the *ibeA* gene is known as the *E. coli* strains virulence factor and plays a significant role in some APEC strains pathogenicity. Barnes et al. [32] mentioned that the intimin produced by the *eaeA* gene found in enterohemorrhagic *E. coli* and enteropathogenic *E. coli*. Yamamoto and Nakazawa [33] found that *astA* gene has been found in enterotoxigenic *E. coli*. Furthermore, Janben et al. [34] mentioned that *astA* was described in APEC strains. Gérard et al. [35] and Skyberg et al. [36] suggested that *cvaC* participates in the synthesis, export, and immunity of a peptide antibiotic Colicin V, which has been discovered in APEC and associated with avian colibacillosis. Dziva and Stevens [37] found that several toxins were described in APEC strains. These involve *cnf1* and cytotoxin designated *VT2e*. Otto et al. [38] and Henderson et al. [39] mentioned that *vat* and *pic* had been reported in APEC and human ExPEC. Hence, these genes have an essential role in APEC and other pathogenic *E. coli* virulence by different mechanisms, and their absence from O27 strain confirms that it is free from virulence and its high chance of being a probiotic.

Referring to the pathogenicity of O27 *in vivo*, all birds of the three groups appeared healthy, full vitality, and

activity with no PM lesions and did not record any mortalities along with the experiment. This result agreed with Otutumi et al. [12] who mentioned that the microorganisms used as probiotics are non-pathogenic components of the normal microflora, such as the lactic acid bacteria or non-pathogenic variants of pathogenic species, such as avirulent mutants of *E. coli*.

Higher performance parameters (BW, weekly feed consumption/gm, and PI) were recorded significantly ($p < 0.01$) in broilers, which administered O27 strain (second and third groups) compared to the control group (first). This result was explained by Yang et al. [40], who mentioned that probiotics improve growth performances by certain mechanisms include intestinal flora alteration, stimulation of the growth of non-pathogenic facultative anaerobic and Gram-positive lactic acid-forming bacteria and hydrogen peroxide, suppression of the growth of intestinal pathogens, and digestion and utilization of nutrients. This also comes in agreement with Otutumi et al. [12], who said that the non-pathogenic variants of pathogenic species can act in the same way as traditional probiotics do as avirulent mutants of *Clostridium difficile*, *E. coli*, and *Salmonella typhimurium*.

Group 2 showed significantly higher performance parameters than group 3. This result exactly comes in agreement with Baldwin et al. [41]. They explained that, at hatch, the first bacteria entering the intestine could attach to epithelial cells without competition and quickly establish, increase in number and become set the intestinal environment to best suit their own needs in terms of metabolite profiles and pH. Bacterial species diversity and distribution constitute the GIT microbiota, fluctuates post-hatch, and becomes as fast as day 3 after the establishment period, and microbiota continue to mature at a slower rate. Hence, the result which can be obtained is better to give the naturally mutant non-pathogenic O27 strain of *E. coli* at the first 3 days than the day 10 in broilers and repeated at 21-day old.

The O27 strain of *E. coli* supplementation did not influence ($p > 0.05$) the hematological and biochemical parameters in the two groups (Groups 2 and 3), and also group 1 exhibits normal hematological parameters. These results typically agreed with Alkhalaf et al. [2] and Kumar et al. [42], who recorded that The hematological and biochemical parameters were not affected ($p > 0.05$) by the dietary supplementation of probiotics.

This study revealed that the supplementation of the O27 strain of *E. coli* in groups 2 and 3 improved the antibody titers to ND comparing to the untreated control group (First). Birds of second group had significantly ($p < 0.01$) higher titers than those in the third group, also its

supplementation improved the antibody titers to IBD ($p > 0.05$) in groups 2 and 3 than in first group. Also, the second group had significantly ($p < 0.05$) higher titers than those in the third group. These results typically agreed with Talebi et al. [42] and Kumar et al. [43]. They recorded that there was a gradual increase in antibody titer against NDV and IBDV due to the supplementation of various probiotics comparing to the control group. This result was explained by Haghghi et al. [44] and Tung and Herzenberg [45], who mentioned that probiotic stimulates naturally occurring antibodies in unimmunized chickens. Functionally, B-cells participate in innate immunity by producing most of the natural serum IgM that protects against invading pathogens before adaptive immune response begins.

In this study, all birds of the three groups showed normal histopathological pictures. Still, the jejunum from birds of groups 2 and 3 showed more tall, intact, and densely packed microvilli and more crypt depth than the control group 1. These results agreed with Bai et al. [46]. They mentioned that Probiotic dietary treatment had been documented to increase the villi height and crypt depth of broilers in the small intestine compared with chickens fed with antibiotics or probiotics feed free. Increased the height of villi is advantageous for broilers because the increased surface area of the villi improved nutrient absorption [47]. Merrifield et al. [48] recorded that broilers' gut health was characterized by intact and densely packed microvilli on administration with probiotics.

Conclusion

The results obtained in our study demonstrate that the O27 strain of *E. coli* is non-pathogenic bacteria because of the absence of the different virulence factors from it and is very close to probiotic *E. coli* strain Nissle 1917, which is a probiotic of *E. coli* origin. Our results about the naturally mutant non-pathogenic O27 strain of *E. coli* and its effects on growth performances and enhancement of immunity in broilers match with the same effects of probiotics, and these candidates will fit to be a good probiotic in the future. The results revealed that the effects of O27 strain at the day 1 old of life for three successive days and repeated at day 21 old are better for improving the performance and immunity of the birds. More research works about the characterized non-pathogenic *E. coli* strain O27 are required for field and commercial use as studying its resistance against the commonly used antibiotics in the poultry industry, studying its gastric juice resistance (low pH level) and bile acid, and studying its ability of inhibition of the growth of other common pathogens of poultry *in vitro* and *in vivo*.

Acknowledgments

The authors would like to acknowledge South Valley University, Qena, Egypt, for supports.

Conflict of interest

The authors declare that there is no conflict of interest.

Authors' contribution

All authors listed have made a substantial, direct, and intellectual contribution to the work and approved it for publication.

Abbreviations

IBDV: infectious bursal disease virus; NDV: Newcastle disease virus; *iroN*: salmochelin siderophore receptor; *crl*: sigma factor-binding protein; *Tsh*: temperature-sensitive hemagglutinin; *Hly*: Hemolysin secretion gene; *papC*: pyelonephritis-associated Pili gene; *kpsMTII*: polysaccharide capsule synthesis gene; *Stx1*: Shiga-toxin1 gene; *Stx2*: Shiga-toxin2 gene; *ibeA*: Brain microvascular endothelial cell invasion; *eaeA*: *E. coli* attaching and effacing gene; *STa*: heat-stable enterotoxin; *LT*: heat-labile enterotoxin; *astA*: east 1 toxin; *cvaC*: colicin V; *VT2e*: verotoxin type 2; *Cnf1*: necrotizing cytotoxic factor type 1; *CFAI*: colonization factor antigen I; *CFAIII*: colonization factor antigen III; *Cs2*: coli surface 2; *CS4*: coli surface 4; *Pic*: serine protease pic autransporter; *Vat*: vacuolating autotransporter toxin; *espP*: serine protease EspP precursor; PI: performance index.

References

- [1] Gadde UD, Oh S, Lillehoj HS, Lillehoj EP. Antibiotic growth promoters virginiamycin and bacitracin methylene disalicylate alter the chicken intestinal metabolome. *Sci Rep* 2018; 8(1):1–8; <https://doi.org/10.1038/s41598-018-22004-6>
- [2] Alkhalif A, Alhaj M, Al-Homidan I. Influence of probiotic supplementation on immune response of broiler chicks. *Egypt Poult Sci* 2010; 30:271–80.
- [3] Dhama K, Verma V, Sawant PM, Tiwari R, Vaid RK, Chauhan RS. Applications of probiotics in poultry: enhancing immunity and beneficial effects on production performances and health – a review. *J Immunol Immunopathol* 2011; 13(1):1–19.
- [4] Pan D, Yu Z. Intestinal microbiome of poultry and its interaction with host and diet. *Gut Microbes* 2014; 5(1):108–19; <https://doi.org/10.4161/gmic.26945>
- [5] Böhm SK, Kruis W. Probiotics: do they help to control intestinal inflammation? *Ann N Y Acad Sci* 2006; 1072(1):339–50; <https://doi.org/10.1196/annals.1326.005>
- [6] Mach T. Clinical usefulness of probiotics in inflammatory bowel diseases. *J Physiol Pharmacol* 2006; 57(Suppl 9):23–33.
- [7] Olnood CG, Beski SSM, Iji P, Choct M. Delivery routes for probiotics: effects on broiler performance, intestinal morphology and gut microflora. *Anim Nutr* 2015; 1:192–202; <https://doi.org/10.1016/j.aninu.2015.07.002>
- [8] Al-Baadani HH, Abudabos AM, Al-Mufarrej SI, Alzawqari M. Effects of dietary inclusion of probiotics, prebiotics and synbiotics on intestinal histological changes in challenged broiler chickens. *S Afr J Anim Sci* 2016; 46:157–65; <https://doi.org/10.4314/sajas.v46i2.6>
- [9] Gesek M, Sokol R, Lambert B, Ostrocka-Domagala I. Effect of effective microorganisms on intestine morphology and morphometry in Japanese quails. *Turk Vet Anim Sci* 2018; 42:285–91; <https://doi.org/10.3906/vet-1801-29>
- [10] Souza de LFA, Araujo DN, Stefani LM, Giometti IC, Cruz-Polycarpo VC, Polycarpo G, et al. Probiotics on performance, intestinal morphology and carcass characteristics of broiler chickens raised with lower or higher environmental challenge. *Austral J Vet Sci* 2018; 50:35–41; <https://doi.org/10.4067/S0719-81322018000100107>
- [11] Fuller R. Probiotics in man and animals. *J Appl Bact* 1989; 66:365–78; <https://doi.org/10.1111/j.1365-2672.1989.tb05105.x>
- [12] Otutumi LK, De Moraes Garcia ER, Góis MB, Loddi MM. Variations on the efficacy of probiotics in poultry. In: Rigobelo EC (ed.) (Rijeka: InTech), Probiotic in animals, London, EC3R 6AF, UK, 2012, pp. 203–230.
- [13] Ahmed SAM, Ahmed IA, Osman N, Shibab El-Hamd DMW. Problem of *Escherichia coli* infection in broilers in qena province. *Assiut Vet Med J* 2017; 63(153):252–64.
- [14] Sambrook J, Fritsch EF, Montias T. Molecular biology. In: Molecular cloning. Laboratory manual. 2nd edition, Cold Spring Harbor Laboratory press, New York, NY, p 268, 1989.
- [15] Schalm OW, Jain NC, Carroll EJ. Veterinary hematology. 3rd edition, Lea and Febiger, Philadelphia, PA, p 21, 1975.
- [16] Coles EH. Veterinary clinical pathology. 4th edition, WB Saunders Co, Philadelphia, PA, pp 53–54, 1986.
- [17] Campbell TW. Avian hematology and cytology. Iowa State University Press, Ames, IA, 1988.
- [18] Caprita R. Principii sitehnici in biochimie. Mirton, Timisoara, UK, pp 125–8, 2001.
- [19] Gustafsson JE. Automated serum albumin determination by use of the immediate reaction with bromocresol green reagent. *Clin Chem* 1978; 24(2):369–73; <https://doi.org/10.1093/clinchem/24.2.369>
- [20] Ross JG, Christie G, Halliday WG, Jones RM. Determination of haematology and blood chemistry values in healthy six-week old broiler hybrids. *Avian Pathol* 1976; 5(4):273–81; <https://doi.org/10.1080/03079457608418196>
- [21] Field, A. Discovering statistics using SPSS (And sex and drugs and rock 'n' roll). 3rd edition, SAGE, London, UK, 2009.
- [22] Pearson K. On the criterion that a given system of deviations from the probable in the case of a correlated system of variables is such that it can be reasonably supposed to have arisen from random sampling. *Philos Mag* 1900; 50:157–75; <https://doi.org/10.1080/14786440009463897>
- [23] Lasaro MA, Salinger N, Zhang J, Wang Y, Zhong Z, et al. F1C fimbriae play an important role in biofilm formation and intestinal colonization by the *Escherichia coli* commensal strain Nissle 1917. *Appl Environ Microbiol* 2009; 75(1):246–51; <https://doi.org/10.1128/AEM.01144-08>
- [24] Sonnenborn U, Schulze J. The non-pathogenic *Escherichia coli* strain Nissle 1917—features of a versatile probiotic. *Microb Ecol Health Dis* 2009; 21(3–4):122–58; <https://doi.org/10.3109/08910600903444267>
- [25] Große C, Scherer J, Koch D, Otto M, Taudte N, Grass G. A new ferrous iron-uptake transporter, EfeU (YcdN), from *Escherichia coli*. *Mol Microbiol* 2006; 62(1):120–31; <https://doi.org/10.1111/j.1365-2958.2006.05326.x>
- [26] Adler C, Corbalán NS, Seyedsayamdost MR, Pomares MF, de Cristóbal RE, Clardy J, et al. Catechol siderophores protect bacteria from pyochelin toxicity. *PLoS One* 2012; 7(10):e46754; <https://doi.org/10.1371/journal.pone.0046754>
- [27] Gao Q, Wang X, Xu H, Xu Y, Ling J, Zhang D, et al. Roles of iron acquisition systems in virulence of extraintestinal pathogenic *Escherichia*

- coli*: salmochelin and aerobactin contribute more to virulence than heme in a chicken infection model. BMC Microbiol 2012; 12:143; <https://doi.org/10.1186/1471-2180-12-143>
- [28] Lelong C, Aguiluz K, Luche S, Kuhn L, Garin J, Rabilloud T, et al. The Crl-RpoS regulon of *Escherichia coli*. Mol Cell Proteom 2007; 6(4):648–59; <https://doi.org/10.1074/mcp.M600191-MCP200>
- [29] Miajlovic H, Cooke NM, Moran GP, Rogers TR, Smith SG. Response of extraintestinal pathogenic *Escherichia coli* to human serum reveals a protective role for Rcs-regulated exopolysaccharide colanic acid. Infect Immun 2014; 82(1):298–305; <https://doi.org/10.1128/IAI.00800-13>
- [30] Compos TA, Stehling EG, Ferreira A, De Castro AFP, Brocchi M, Da Silveira WD. Adhesion properties, fimbrial expression and PCR detection of adhesin-related genes of avian *Escherichia coli* strains. Vet Microbiol 2005; 106(3):275–85; <https://doi.org/10.1016/j.vetmic.2004.12.025>
- [31] Germon P, Chen YH, He L, Blanco JE, Bree A, Schouler C, et al. *ibeA*, a virulence factor of avian pathogenic *Escherichia coli*. Microbiol 2005; 151(4):1179–86; <https://doi.org/10.1099/mic.0.27809-0>
- [32] Barnes HJ, Nolan lk, Vaillancourt JA. Colibacillosis in Saif YM, Benson HJ. Microbiological applications. 8th edition, McGraw Hill, New York, NY, p 95, 2008. Bacterial Population Counts. ICBN# 0-07-231889-9.
- [33] Yamamoto T, Nakazawa M. Detection and sequences of the enteroaggregative *Escherichia coli* heat-stable enterotoxin 1 gene in enterotoxigenic *E. coli* strains isolated from piglets and calves with diarrhea. J Clin Microbiol 1997; 35(1):223–7; <https://doi.org/10.1128/JCM.35.1.223-227.1997>
- [34] Janben T, Schwarz C, Preikschat P, Voss M, Philipp HC, Wieler LH. Virulence associated genes in avian pathogenic *Escherichia coli* (APEC) isolated from internal organs of poultry having died from colibacillosis. Int J Med Microbiol 2001; 291(5):371–8; <https://doi.org/10.1078/1438-4221-00143>
- [35] Gérard F, Pradel N, Wu LF. Bactericidal activity of colicin V is mediated by an inner membrane protein, SdaC, of *Escherichia coli*. J Bacteriol 2005; 187(6):19–50; <https://doi.org/10.1128/JB.187.6.1945-1950.2005>
- [36] Skyberg JA, Johnson TJ, Johnson JR, Clabots C, Logue CM, Nolan LK. Acquisition of avian pathogenic *Escherichia coli* plasmids by a commensal *E. coli* isolate enhances its abilities to kill chicken embryos, grow in human urine, and colonize the murine kidney. Infect Immun 2006; 74(11):6287–92; <https://doi.org/10.1128/IAI.00363-06>
- [37] Dziva F, Stevens MP. Colibacillosis in poultry: unravelling the molecular basis of virulence of avian pathogenic *Escherichia coli* in their natural hosts. Avian Pathol 2008; 37(4):355–66; <https://doi.org/10.1080/03079450802216652>
- [38] Otto BR, Van Dooren SJ, Nuijens JH, Luirink J, Oudega B. Characterization of a hemoglobin protease secreted by the pathogenic *Escherichia coli* strain EB1. J Exp Med 1998; 188(6):1091–103; <https://doi.org/10.1084/jem.188.6.1091>
- [39] Henderson IR, Czczulin J, Eslava C, Noriega F, Nataro JP. Characterization of Pic, a secreted protease of *Shigella flexneri* and enteroaggregative *Escherichia coli*. Infect Immun 1999; 67(11):5587–96; <https://doi.org/10.1128/IAI.67.11.5587-5596.1999>
- [40] Yang Y, Iji PA, Choct M. Dietary modulation of gut microflora in broiler chickens: a review of the role of six kinds of alternatives to in-feed antibiotics. Worlds Poult Sci J 2009; 65(1):97–114; <https://doi.org/10.1017/S0043933909000087>
- [41] Baldwin S, Hughes RJ, Van TTH, Moore RJ, Stanley D. At-hatch administration of probiotic to chickens can introduce beneficial changes in gut microbiota. PLoS One 2018; 13(3):e0194825; <https://doi.org/10.1371/journal.pone.0194825>
- [42] Kumar L, Singh PK, Kumar M. Effect of dietary supplementation of combination of probiotics on the growth performance and immune response of broiler chickens. Anim Nutr Feed Technol 2013; 13(1):15–25; <https://doi.org/10.1080/03079450802356995>
- [43] Talebi A, Amirzadeh B, Mokhtari B, Gahri H. Effects of a multi-strain probiotic (PrimaLac) on performance and antibody responses to Newcastle disease virus and infectious bursal disease virus vaccination in broiler chickens. Avian Pathol 2008; 37(5):509–12; <https://doi.org/10.1080/03079450802356995>
- [44] Haghighi HR, Gong J, Gyles CL, Hayes MA, Zhou H, Sanei B, et al. Probiotics stimulate production of natural antibodies in chickens. Clin Vaccine Immunol 2006; 13:975–80; <https://doi.org/10.1128/CVI.00161-06>
- [45] Tung JW, Herzenberg LA. Unraveling B-1 progenitors. Curr Opin Immunol 2007; 19(2):150–5; <https://doi.org/10.1016/j.coi.2007.02.012>
- [46] Bai SP, Wu AM, Ding XM, Lei Y, Bai J, Zhang KY, et al. Effects of probiotic-supplemented diets on growth performance and intestinal immune characteristics of broiler chickens. Poult Sci 2013; 92(3):663–70; <https://doi.org/10.3382/ps.2012-02813>
- [47] Awad WA, Ghareeb K, Abdel-Raheem S, Böhm J. Effects of dietary inclusion of probiotic and synbiotic on growth performance, organ weights, and intestinal histomorphology of broiler chickens. Poult Sci 2009; 88(1):49–56; <https://doi.org/10.3382/ps.2008-00244>
- [48] Merrifield DL, Dimitroglou A, Bradley G, Baker TM, Davies SJ. Soybean meal alters autochthonous microbial populations, microvilli morphology and compromises intestinal enterocyte integrity of rainbow trout, *Oncorhynchus mykiss* (Walbaum). J Fish Dis 2009; 32(9):755–66; <https://doi.org/10.1111/j.1365-2761.2009.01052.x>