

SHORT COMMUNICATION

The potency of eel meat (*Monopterus albus*) extract on tumor necrosis factor alpha (TNF- α) expression and epidermal thickness incision wounds on rats (*Rattus norvegicus*)

Viski Fitri Hendrawan, Fairuz Ikhsan, Ani Setianingrum, Tiara Widyaputri
Department of Veterinary Reproduction, University of Brawijaya, Malang, East Java 65151, Indonesia

ABSTRACT

Objective: The objective of this study is to determine the effect of eel meat (*Monopterus albus*) extract ointment on an incision.

Materials and Methods: The experimental animals used in this study were 20 male rats (*Rattus norvegicus*), *Wistar*, weighing 150–200 gm and aged 8–12 weeks. This study uses complete random design and is divided into four groups. In the negative control group, group treatment was carried out on the healthy rat. In the positive control group, the incision was performed without any therapy. In the T1 and T2 groups, group treatment was performed with a dose of 2% and 5% eel (*M. albus*) extracts. The TNF- α expression was analyzed by the immunohistochemistry (IHC) technique and epidermal thickness by Masson's Trichrome (MT) staining. Data analysis of TNF- α expression and epidermal thickness was done using one-way analysis of variance and the Tukey test with a confidence level of 95% ($\alpha = 0.05$).

Results: The results showed that the eel (*M. albus*) extract therapy, with a concentration of 2% and 5%, significantly ($p < 0.05$) reduced the TNF- α expression and increased the epidermal thickness.

Conclusion: It can be concluded that the administration of eel (*M. albus*) extract therapy could help to reduce TNF- α expression and increase epidermal thickness in rat incision wounds.

ARTICLE HISTORY

Received September 27, 2019
Revised November 12, 2019
Accepted November 15, 2019
Published December 14, 2019

KEYWORDS

Eel meat extract; epidermis; incision wounds; skin; TNF- α



This is an Open Access article distributed under the terms of the Creative Commons Attribution 4.0 Licence (<http://creativecommons.org/licenses/by/4.0>)

Introduction

A wound is a condition where there is damage or loss of some human body tissues and a condition where there is a loss of epithelial integrity from the skin. The role of the skin is very important for the body, such as temperature regulation, excretion, protection, sensory, and formation of vitamin D. Wounds can be caused by a physical injury/trauma by sharp and blunt objects, chemicals, temperature changes, electric shock, explosion, and biting [1]. By definition, a wound is a breakdown or loss of cellular and anatomic continuity, with impairment of the tissue's protective or physiological functions; trauma is a physical injury or a wound caused by external force or violence [2]; and an incision wound is cut wound caused by sharp objects that reach a certain depth, so incision wound is open wound. The open wound must be treated immediately so that no infection occurs and damage of blood vessels and tissues is minimized [3].

Wound healing is a complex process that integrates the functions of formed blood elements (erythrocyte, leucocyte, and thrombocyte), extracellular matrix, parenchymal cells, and soluble mediators. In an uncomplicated wound, the repair process follows a fairly consistent time sequence [2]. The use of drugs aims to accelerate the wound-healing process. The used drugs can be in the form of chemical drugs or natural herbal medicines. Chemical drugs, often used by people to heal wounds, contain free iodine and polyvinylpyrrolidone, which have strong antimicrobial effects, but can be toxic to body cells, cause skin irritation and allergic reactions in the form of redness, swelling, and itching of the skin; therefore, other alternatives are needed. Recently, research on alternative medicine from plants is growing rapidly, but the use of animals/animal extracts as alternative treatment materials is still not widely known. One of the natural compounds, which can be used as an

Correspondence Viski Fitri Hendrawan ✉ viski_hendrawan88@yahoo.com 📧 Department of Veterinary Reproduction, University of Brawijaya, Malang, East Java 65151, Indonesia.

How to cite: Hendrawan VF, Ikhsan F, Setianingrum A, Widyaputri T. The potency of eel meat (*Monopterus albus*) extract on tumor necrosis factor alpha (TNF- α) expression and epidermal thickness incision wounds on rats (*Rattus norvegicus*). *J Adv Vet Anim Res* 2020; 7(1):77–82.

alternative treatment for open wounds, is obtained from the eel. Eel is one of fisheries commodities which is relatively easy to find in rice fields. Eels are cheap and contain proteins, iron, phosphorus, vitamin A, vitamin B, and fats; therefore, eels might be used for wound-healing treatment [4]. Eel fish is one of the most common fish species in Indonesia, Malaysia, Bangladesh, Africa, India, Myanmar, and Australia. Eel fish contains vitamin A, B1, B2, B6, C, D, Docosahexaenoic acid, Eicosapentaenoic acid, and proteins, or usually known as omega-3, as well as some other minerals [5].

Proteins in eel contain amino acids such as leucine, lysine, aspartic acid, and glutamic acid. Aspartic acid and glutamic acid are important for skin formation, collagen formation, the formation of pro-inflammatory cytokines, maintaining lymphocyte function, and the formation of fibroblasts and macrophages, and might suppress the inflammatory process during the wound-healing phase [6].

Wound healing is satisfactory if the inflammation is low and the growth of new tissues is high. Loss of inflammatory phase can be determined by measuring inflammation biomarkers, one of them is TNF- α . The growth of new tissues in the skin can be characterized by the presence of a formed layer of the epidermis. Therefore, wound healing can be determined by the decrease of TNF- α level and the presence of a formed epidermis layer in the injured skin [7].

Therefore, TNF- α cytokine and epidermal thickness are chosen as inflammatory parameters in the incision wound-healing process from animal models. The administration of the eel extract ointment containing amino acids and fatty acids is expected to increase the thickness of the epidermis and reduce TNF- α expression. The wound will immediately undergo the proliferation stage, and, through this study, we can determine the eel extract potential on the wound-healing process based on the epidermal thickness and TNF- α expression.

Materials and Methods

Ethical approval

The use of animal models in this study has passed the ethical certification from the Ethical Committee of Research Brawijaya University (KEP-UB), with registration number: 1066-KEP-UB.

Materials and tools

The tools used in this study include animal cages, a digital scale, a set of surgical instruments, a steamer, heat-resistant bowls, filter paper, a centrifuge, mortar, spatula, ointment pots, organ pots, sterile gauze, and microscopes.

The materials were white rats (*Rattus norvegicus*), feed and drinking water for animal models, husks, eels,

water, ketamine xylazine as local anesthesia, vaseline album, *Pulvis Gummi Arabicum* (PGA), multilevel alcohol concentration (70%, 80%, 90%, 100%), emulsion oil, 10% formalin, aquadest, paraffin, Phosphate Buffered Saline (PBS; pH 7.4), xylol solution, and Masson's Trichome staining.

Animal models preparation

The animal model used is a 2–3 months old male *R. norvegicus* Wistar strain with a bodyweight of 150–200 gm. Animals were acclimatized for 7 days, and then the rats were divided into four groups: negative (healthy) control group, positive control (CP) group (incised rat), and T1 and T2 treatment groups which received therapy with a concentration of 2% and 5% and consisted of five rats per group.

Rats were incised on the eighth day: a 2 cm long cut with a depth reaching the subcutaneous dorsal region 0.5 cm from the right vertebrae bone. Before the incision was made, the incision location was shaved until it was clean, smeared with cotton containing 70% alcohol for sterilization, and anesthesia was injected intramuscularly using ketamine and xylazine to easily incise the animal models.

Euthanasia of animal models and organ isolation

Euthanasia and removal of animal skin tissues were conducted 14 days after the incision or the twenty-first day. Euthanasia of the rats was carried out on the cervical bone by the dislocation method. The American Veterinary Medical Association recommends this method in rats weighing ≤ 200 gm, because if the rat's weight is too heavy, then there will be a large muscle mass in the cervical area, making it difficult for cervical dislocation. Excision was conducted in the healed wound using a little bit of normal skin tissue around 0.5 cm from the edge of the wound. Excision was then added into a 10% formalin solution before histology preparations were made.

Eel extraction procedure

Eel extraction was conducted through steaming and pressing. Eels were washed, their internal organs were cleaned, and steamed at a temperature of 70°C–80°C for 30 min. Eel extract was collected and filtered using a filter cloth, and then the cloth was squeezed to complete the extraction. After filtering, the extract was centrifuged for 60 min at a speed of 6,000 rpm, forming oil, water, and lump layers. The oil and water layers were taken out [8].

The eel extract ointment was made by homogenizing the eel extract (*Monopterus albus*) with 2% and 5% concentration and formulating the extract with a PGA ointment base ingredient (100 gm) and vaseline album (100 gm).

Eel extract treatment

Eel extract (*M. albus*) was given for 14 days twice a day. Eel extract (*M. albus*) was given topically. Treatment group 1 was given 2% concentration and treatment group 2 was given 5% concentration.

Making TNF- α Chemical Process Industries (CPI) preparations

The staining method began by immersing slide preparations on xylol I, xylol II and multilevel ethanol concentration (100%, 90%, 80%, 70%). These slides were rinsed thrice with PBS (pH 7.4) for 3 min, dripped with H₂O₂ for 20 min, and blocked with 1% Bovine Serum Albumin for 30 min at room temperature. Afterward, the tissues were again rinsed thrice with PBS (pH 7.4) for 3 min and, subsequently, incubated with primary antibodies. The primary antibody used was TNF- α anti-rat primary antibody (1:50 dilution) overnight with at 40°C, and then it was rinsed thrice with PBS (pH 7.4) for 3 min. After that, the preparations were incubated with secondary antibodies labeled rabbit anti-rat IgG biotin for 1 h at room temperature. Fifty-three slides were again rinsed thrice with PBS (pH 7.4) for 3 min.

Slides that underwent the abovementioned stages were then given Streptavidin Horseradish Peroxidase (SA-HRP) drops for 40 min and were again rinsed thrice with PBS (pH 7.4) for 3 min. Furthermore, it was dropped with Diaminobenzidine chromogen for 10 min and again rinsed thrice with PBS (pH 7.4) for 3 min. Staining used was Mayer Hematoxylin for 5 min. Slides were rinsed again with running water and aquadest, and then dried. In the mounting stage, the slides were immersed in an entellant solution and covered with a glass cover.

Observation of TNF- α expression

Immunohistochemistry (IHC) aims to calculate TNF- α expression on the skin. The calculation of TNF- α expression was carried out with a 400 \times magnification microscope in five viewing fields. Observations were made on inflammatory cells and surrounding tissues, and then the observations were photographed. Photographs from the microscope were processed using ImmunoRatio software to calculate the increase in TNF- α expression, which was marked by an increase in the area which was brown colored.

Skin histopathology slide preparations

Slide preparations began with deparaffinization and rehydration processes. Before staining, Bouin's solution was first heated in a waterbath at a temperature of 56°C–64°C and the water bath was kept in a well-ventilated area.

Different solutions were dropped on the slides for staining. About 5–10 drops of Bouin's solution was dropped for 60 min. Next, the slides were rinsed with running water and aquadest, one time each. Weigert A and Weigert B were mixed with a ratio of 1:1 in the tissue for 5–10 min in a humid state. Afterward, slides were rinsed with running water and aquadest for 2 min each. About 5–10 drops of acid fuchsin solution was dropped for 5–15 min. The slides were rinsed again with aquadest. About 5–10 drops of phosphomolybdic solution were dropped for 10–15 min. Afterward, the coloring process was carried out by dropping 5–10 drops of Anilin Blue solution into the slides for 5–10 min. Slides were rinsed again with aquadest. One percent acetic acid solution was given in drops into the slides for 3–5 min. Dehydration was done using absolute alcohol I and II for 5 min each. After the staining and dehydration processes were completed, the clearing stage was carried out using Xylol I, II, and III for 5 min each. The slides were cleaned with 1–2 drops of the entellant solution. Slides were covered with a glass cover and left to dry.

Measurement of epidermal layer thickness

Measurement of epidermal thickness was done by examining the previously made histology preparations. Skin slide preparations were stained with MT (Masson's Trichrome). Epidermis thickness was measured using a microruler from stratum corneum to stratum basalis through Raster imageJ software, and the data obtained were analyzed using SPSS with one-way analysis of variance (ANOVA) statistical analysis followed by the Tukey test with 95% confidence rate.

Data analysis

The parameters used in this study were TNF- α expression and epidermal thickness. TNF- α expression data were analyzed by observing five viewing fields (upper left, upper right, middle, lower left, and lower right) with a magnification of 400 \times , carried out using the help of ImmunoRatio software in the form of percentage, and then described using standard deviation in the form of numbers [9]. Epidermal thickness was measured by a microruler on raster imageJ software from stratum basalis to stratum corneum, and then the obtained results were analyzed using SPSS with one-way ANOVA statistical analysis followed by the Tukey test with 95% confidence rate [10].

Results and Discussion

Tumor necrosis factor alpha (TNF- α) expression on skin

The results of tumor necrosis factor alpha (TNF- α) expression in rats (*R. norvegicus*) treated with eel extract (*M. albus*) ointment therapy using Chemical Process

Industries (CPI) technique were shown with brown color expression in the tissues (Fig. 1).

Group negative control (CN) (Fig. 1) as a CN described TNF- α expression under normal skin tissue conditions. TNF- α is a component of immunity that is normally present in healthy tissues. TNF- α will remain expressed in small amounts of skin tissue, and will only increase if the skin has a wound or disease. This is evident in the results of this study, where CN still has a brownish color which signifies TNF- α expression, even with low sharpness and is localized to epidermal basal cells, dermis dendritic cells, and endothelial cell cytoplasm.

In CP (Fig. 1) as CP, the brown color dominates the entire dermis, which is contrary to the CN group. This group is a CP group, in which animal models were given incision wounds but were not given any therapy. This causes inflammatory agents, such as TNF- α , to be highly expressed than the groups receiving the treatment. TNF- α expression in treatment group 1 (T1) (Fig. 1) with 2% eel extract (*M. albus*) showed a decrease in TNF- α expression with brown color appearance which was less observed compared to the CP group, but the decrease of TNF- α expression in treatment group (T1) has not reached the same result as in the CN group. The difference was seen in the treatment group (T2) (Fig. 1) compared to the CP. T2 has a blue color dominance in dermis and epidermis, whereas CP has a lot of brown color dominance. This shows that the treatment group (T2) with 5% eel extract (*M. albus*) has the lowest TNF- α expression.

The results of TNF- α expression were measured using the ImmunoRatio software, and then analyzed statistically with the one-way ANOVA method ($p < 0.05$), followed by the Tukey α test = 0.05 on TNF- α expression (Table 1).

The group that is significantly different from the CP group is the T2 group. Based on the mean value, the T2 group is the group that has the least number of inflammatory cells compared to T1. T2 group (12.07 ± 4.22) is the treatment group that has the lowest TNF- α expression. TNF- α is the

main cytokine that controls the inflammatory response, so it can be an indicator of how high the inflammatory activity in the tissue is. One of the fatty acids contained in eels includes linolenic acid (omega-3). According to Andrie and Sihombing [8], linolenic acid (omega-3) acts as an anti-inflammatory which works by breaking the arachidonic acid cycle, therefore inhibiting the infiltration of inflammatory cells, decreasing the inflammatory cells in the tissues, and reducing the TNF- α level. The effect of wound healing is due to the anti-inflammatory activity of omega-3. Consumption of foods containing omega-3 plays an important role in wound healing by altering the fibroblastic or maturation phase of the healing responses [5]. Based on the Tukey test, TNF- α expression in T2 and control group did not have a significant difference. Healthy tissue in CN still expresses TNF- α because it is a normal component of the immune system, however, in small amounts.

CP group (46.61 ± 8.63) had the highest TNF- α expression compared to others because of inflammation in tissue after incision and no therapy was given to reduce inflammation. In the hemostasis phase, thrombocytes or platelet aggregation will occur. Aggregated platelets will trigger an inflammatory phase characterized by activation of platelet-derived growth factor and transforming growth factor beta, both of them will initiate an inflammatory response by attracting inflammatory cells (neutrophils and macrophages) around the wound. Macrophages that are in the network then release pro-inflammatory cytokines, one of which is TNF- α .

T1 group (27.12 ± 5.72) had higher TNF- α value than T2 but lower than CP. Based on the Tukey test, this group did not have a significant difference from CN or CP group. Therefore, it was concluded that of the two treatment groups, only the T2 group had the lowest effect of reducing TNF- α expression in incision wounds. This is due to the high concentration of amino acids and fatty acids in eel extract (*M. albus*) 5% ointment. In this study, the use of 5% eel extract (*M. albus*) can reduce TNF- α expression in incision wounds of rats (*R. norvegicus*), because the

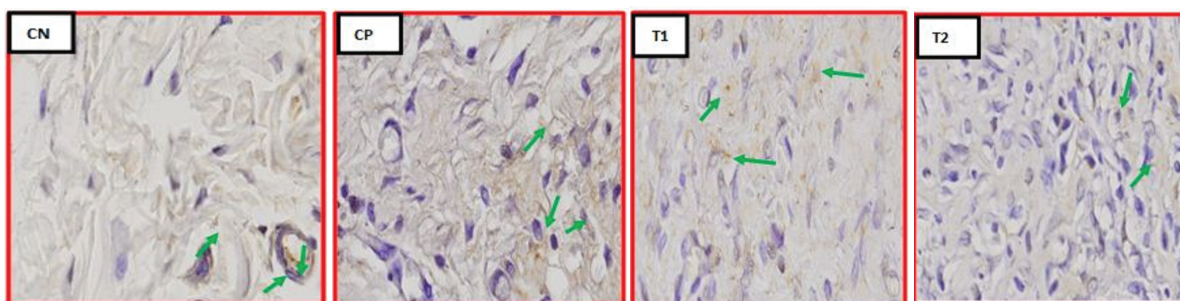


Figure 1. Expression of TNF- α by immunohistochemistry (IHC) method in groups CN, CP, T1, and T2 with 400 \times magnification. TNF- α expression was shown by green arrows.

abovementioned results show that TNF- α expression has decreased and did not experience significant differences with the CN group.

Wound healing is a complex process requiring cell migration, inflammation, angiogenesis, granulation tissue formation, re-epithelization, and extracellular matrix remodeling. Resolution of inflammation is essential to successful wound healing, and chronic inflammation can lead to poor healing outcomes [11]. Rat wounds with eel meat extract demonstrated a significantly lower number of pro-inflammatory cytokines such as TNF- α .

Increased epidermal thickness

Histopathology depiction of epidermal thickness in rats (*R. norvegicus*) treated with eel extract (*M. albus*) ointment with MT staining was measured using a microruler. SoftwareImageJ Raster can be seen in Figure 2.

Table 1 shows that the growth of epidermis in each treatment shows a significant difference, which is depicted by an increase of mean epidermal thickness using a, b, and c notations. This shows that the eel extract (*M. albus*) ointment with a concentration of 5% is the best concentration for therapeutic doses with a mean epidermal thickness reaching 48.252 μm .

The CN group is a group of rats that were not given any treatment. The CN rat treatment group became an indicator of epidermal thickness in normal rats with a mean thickness of 28.47 μm . MT staining was used and is also

called connective tissue staining technique because it is used to show the supporting elements of connective tissue. In MT staining, stained small molecules will penetrate and stain tissue elements and the staining of larger molecules will penetrate the same elements as in smaller molecules and will be replaced by larger molecules. This staining will show red color for skin tissue cytoplasm, while cell nucleus will be colored purple in a normal intact epidermal layer in rats of CN group. Epidermis will appear more regular compared to skin epidermis in treated rats (*R. norvegicus*).

The CP group consisted of rats that were incised but were not given any therapy. CP group showed a mean epidermal thickness of 33.28 μm , but the epithelial growth seen at CP was irregular and did not look very clear. This is because in group CP, there is still an inflammatory process and TNF- α level in the network is still high, therefore epithelial growth and re-epithelization processes cannot run well and fast.

T1 group is the treatment group that was given the eel extract (*M. albus*) ointment with a concentration of 2% and showed an epithelial growth with a mean thickness of 41.85 μm . Epithelial growth seen in T1 was significantly different compared to T2 treatment. T2 treatment group is the treatment group that was given eel extract (*M. albus*) ointment with a concentration of 5% and showed a significantly better epithelial growth than the other treatment groups. It has a mean thickness of

Table 1. Results of statistical analysis of tumor necrosis factor (TNF- α) expressions and average thickness of epidermis in rat skin.

Treatment	Average expression of TNF- α \pm standard deviation (SD)	Average thickness of epidermis (μm) \pm SD
CN	9.54 \pm 3.01 ^a	28.47 \pm 8.35 ^a
CP	46.61 \pm 8.63 ^c	33.28 \pm 6.02 ^b
T1	27.12 \pm 5.72 ^b	41.85 \pm 5.31 ^b
T2	12.07 \pm 4.22 ^a	48.25 \pm 4.54 ^c

Differences in a, b, c notation indicate a significant difference ($p \leq 0.05$) between groups. CN = Negative Control, CP = Positive Control, T1 = Treatment 1, T2 = Treatment 2.

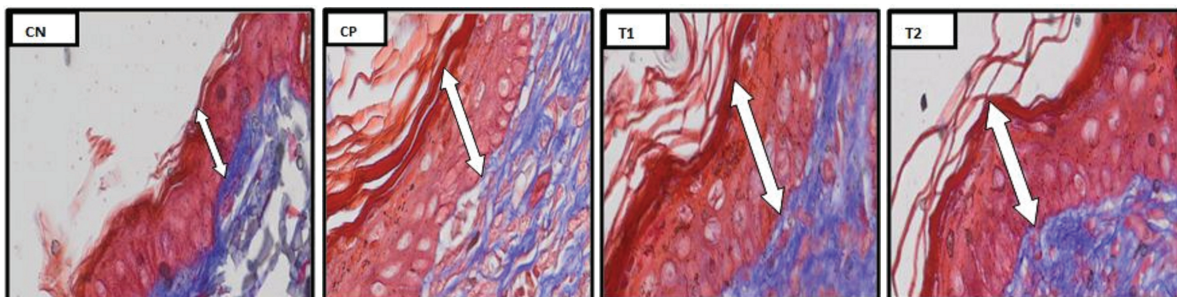


Figure 2. Overview of skin histology using the Masson's Trichrome (MT) staining method in the CN, CP, T1, and T2 groups with a 400 \times magnification. Reepithelization area was indicated by white arrow.

48.25 μm . This proves that there is fatty acid contained in eels, including linolenic acid (omega-3). According to Andrie and Sihombing [8], linolenic acid (omega-3) acts as an anti-inflammatory which works by breaking the arachidonic acid cycle, therefore inhibiting infiltration of inflammatory cells and decreasing inflammatory cells in the tissues, reducing TNF- α level. When inflammation cells decrease and TNF- α level in wound tissue is small, inflammation will end abruptly and the wound will undergo proliferation phase. It will undergo re-epithelialization to form the epidermis layer.

The process of wound healing is a biological process that occurs in the body. In T1, there was an epithelial growth with a mean thickness of 41.85 μm , and T2 mean thickness was 48.25 μm , indicating an epidermis thickness that was far from CN. CN is an indicator of epidermal thickness in normal rats. The results show that T1 and T2 are still in the proliferation phase and not in the re-modeling or maturase phase. When collagen production and degradation level reach the balance, the maturation phase of wound tissue begins. This phase might occur until 1 year, depending on the size of the wound and the method of closure. During the maturation process, type III collagen, which plays an important role during the proliferation phase, will gradually decrease and will be replaced with stronger type I collagen. These collagen fibers will be arranged and ordered along the wound line to restore the skin back to normal. When the wound-healing process has passed the maturation phase, the wound is healed and the wound-healing process is completed [12]. Omega-3 and other fatty acids have been known to have activities the decreasing of blood fats, hepatoprotective, anti-inflammatory, and oxidative stress. Fatty acids play a role in the wound-healing process and also play a role in the immune system in the process of formation of collagen and epithelial tissue in the wound [5].

In this study, the administration of eel extract (*M. albus*) ointment showed significant results because the *p* value was < 0.05 in the re-epithelialization process. Based on the results of the statistical analysis, the 5% treatment group was the group with the best dose compared to other treatment groups. This proves that there is a quick wound-healing process. Epithelial thickness can indicate the process of reepithelization which takes place more quickly and the inflammatory phase which can be passed more quickly.

Conclusion

Based on this study, it can be concluded that eel extract (*M. albus*) ointment can reduce TNF- α expression and increase epidermal thickness in incision wounds on rats (*R. norvegicus*).

Acknowledgment

The authors would like to thank the Faculty of Veterinary Medicine, Brawijaya University, for providing all supporting facilities.

Conflict of interests

The authors declare that they have no conflict of interests.

Authors' contribution

Viski Fitri Hendrawan designed the study, interpreted the data, and drafted the manuscript. Fairuz Ikhsan was involved in collecting data and also contributed to manuscript preparation. Ani Setianingrum and Tiara Widayaputri took part in preparing and critical checking of this manuscript.

References

- [1] Nasution AAM, Batubara DE. Perbandingan Efektifitas Ekstrak Daun Pepaya (*Carica papaya*) 100% dan Gentamisin Krim 0,1% Terhadap Ketebalan Epitel pada Luka Sayat Tikus Wistar (*Rattus norvegicus*). Jurnal Ibnu Sina Biomedika 2017; 1(1):1-6.
- [2] Pavletic MM. Atlas of small animal wound management and reconstructive surgery fourth edition. WILEY Blackwell, USA, pp 19-20, 2018; <https://doi.org/10.1002/9781119267539>
- [3] Dorland W. Kamus Kedokteran Dorland. EGC, Jakarta, 2006.
- [4] Rukmana R. Budi Daya Belut. Penerbit Kanisius, Yogyakarta, pp 9-15, 2003.
- [5] Sasongko H, Bayu AS, Renita WNH, Raka SWS, Tiara AS. The effect of hydrocarbon ointment eel fish (*Anguilla bicolor bicolor*) and snakehead fish (*Channa striata*) oil for wound healing in Wistar rats. In AIP Conference Proceedings, pp 050001-6, 2019; <https://doi.org/10.1063/1.5061899>
- [6] Mukhtiani M. Menggeluti Bisnis Belut Seri Perikanan Modern. Pustaka Baru Press, Yogyakarta, pp 18-25, 2011.
- [7] Holzman G, Raffel T. Surgical patient care for veterinary technicians and nurses. Wiley Blackwell, Hoboken, pp 160-1, 2015; <https://doi.org/10.1002/9781119421337>
- [8] Andrie M, Sihombing D. Efektivitas Sediaan Salep yang Mengandung Ekstrak Ikan Gabus (*Channa striata*) pada Proses Penyembuhan Luka Akut Stadium II Terbuka pada Tikus Jantan Galur Wistar [Skripsi]. Universitas Tanjungpura, Pontianak, Indonesia, 2017.
- [9] Sabirosi A. Pemanfaatan Flavonoid di Bidang Kedokteran Gigi. Majalah Kedokteran Gigi Edisi Khusus Temu Ilmiah Nasional III. FKG Unair, Surabaya, Indonesia, pp 81-7, 2003.
- [10] Kusrieningrum RS. Buku Ajar Perancangan Percobaan. Fakultas Kedokteran Hewan Universitas Airlangga, Surabaya, 2008.
- [11] Lee DE, Nagi A, Davendra KA. Mesenchymal stem cells and cutaneous wound healing: novel methods to increase cell delivery and therapeutic efficacy. Stem Cell Res Ther 2016; 7(37): 1-8; <https://doi.org/10.1186/s13287-016-0303-6>
- [12] Palumpun FE, Wiraguna AGP. Pemberian ekstrak daun sirih (*Piper betle*) secara topikal meningkatkan epidermis, jumlah fibroblast, dan jumlah kolagen dalam proses penyembuhan luka pada tikus jantan galur wistar (*Rattus norvegicus*). Jurnal e-Biomedika 2017; 5(1); <https://doi.org/10.35790/ebm.5.1.2017.15037>