

ORIGINAL ARTICLE

The effects of laser diode treatment on liver dysfunction of *Mus musculus* due to carbofuran exposure: An *in vivo* study

Suryani Dyah Astuti¹, Vivi Sumanti Victory¹, Amalia Fitriana Mahmud¹, Alfian Pramudita Putra², Dwi Winarni³

¹Department of Physics, Faculty of Science and Technology, Universitas Airlangga, Surabaya, East Java 60115, Indonesia

²Biomedical Engineering Study Program, Department of Physics, Faculty of Science and Technology, Universitas Airlangga, Surabaya, East Java 60115, Indonesia

³Department of Biology, Faculty of Science and Technology, Universitas Airlangga, Surabaya, East Java, 60115, Indonesia.

ABSTRACT

Objective: The aim of this study is to determine the effect of laser diode as an alternative treatment on liver dysfunction (*in vivo* study) that is caused by carbofuran using male mice (*Mus musculus*) strain Balb/C.

Materials and Methods: The samples were divided into three groups, namely, Group C–L– (control group, no treatment), Group C+L– (only treated by carbofuran treatment), and Group C+L+ (treatment group, treated by carbofuran and laser-puncture) with five replications each. After being treated, each liver slice of samples was observed using microscope to get the histology result and then scored.

Results: Carbofuran contamination can lead to inflammation of cells and necrosis. The histology results and the scoring test showed that the liver cells repair with the energy dose of laser diode at 0.5 and 1.0 Joule.

Conclusion: The optimum energy dose in this study was 1.0 Joule which had the closest score of inflammatory cells and necrosis to normal liver cells.

ARTICLE HISTORY

Received July 16, 2019

Revised September 25, 2019

Accepted September 25, 2019

Published October 23, 2019

KEYWORDS

Photobiomodulation; laser diode; liver dysfunction; *Mus musculus*.



This is an Open Access article distributed under the terms of the Creative Commons Attribution 4.0 Licence (<http://creativecommons.org/licenses/by/4.0>)

Introduction

Carbofuran (2, 3-dihydro-2,2-dimethyl-7-benzofuranyl-N methyl carbamate) is one of the common pesticides that is used to eradicate pests, such as insects, mites, and nematodes in the soil [1–3]. This pesticide is commonly used in agricultural and household [4,5]. In 2012, there was at least over 1 billion pound of pesticides usage in worldwide and it has dramatically increased for the last two decades [6,7]. Due to the widespread use of this chemical substance in agricultural and household, its residues in food may be harmful to non-targeting organisms, especially humans [8,9].

The toxicity of carbofuran ranges as moderate-high, highly toxic by inhalation, ingestion and moderately toxic by dermal absorption [6,8]. Carbofuran contamination has caused many negative effects on organism such as an oxidative stress and impairment on motoric, cognitive, and memory functions [3,10]. Some studies

have also proven that carbofuran effects are significantly harmful on the liver functions, especially result in the Non-Alcoholic Fatty Liver Disease (NAFLD) [7,11]. The dysfunction of the liver has become a serious illness in human considering that the liver is one of the important organs. In addition, NAFLD is the most common cause of chronic liver disease and a major cause of liver disease worldwide; it is even predicted to become the main reason of liver transplantation in 2030 [12,13]. Recent clinical medication on liver dysfunction is relatively expensive and has negative impacts if it does not handled properly. As carbofuran could lead to the liver dysfunction and the use of it has become usual in daily life, the alternative treatment for it is needed. One of the therapeutic modalities of chronic liver disease is acupuncture therapy by using a laser diode.

Correspondence Suryani Dyah Astuti ✉ suryanidyah@fst.unair.ac.id 📧 Department of Physics, Faculty of Science and Technology, Universitas Airlangga, Surabaya, East Java 60115, Indonesia.

How to cite: Astuti SD, Victory VS, Mahmud AF, Putra AP, Winarni D. The effects of laser diode treatment on liver dysfunction of *Mus musculus* due to carbofuran exposure: An *in vivo* study. J Adv Vet Anim Res 2019; 6(4):499–505.

Laser has a coherent and monochromatic beam, so its energy is more focused than other conventional light sources [14]. One of the laser interactions with tissue is the photochemical effect. This laser property is used for various applications in the medical field [15,16]. Recent research studies have mentioned laser as an alternative treatment of antimicrobial, antifungal, and photobiomodulation that is relatively inexpensive and has no negative effects [17–20]. In this study, red laser diode was used as laser-puncture because of its capability to penetrate is better than other visible light laser diodes.

Laser-puncture treatment uses the photon energy of laser on acupuncture point. Acupuncture point consists of active cells that are sensitive to environmental changes caused by energy pressure [21]. The source of light that is used as the stimulation to the acupuncture points is commonly on 632–685 nm of wavelength with 5–30 mW [22,23]. Irradiation is carried out to the acupuncture point so that the cells repair on inflammation and necrosis cells can occur [24]. A recent study used the red laser with 650 nm and 36 mW of power showed that it can increase the number of nucleated cells in the bone marrow, decrease the unfavorable effects of cyclophosphamide on the cell cycle, induce the cell cycle towards proliferation, decrease apoptosis, improve the intramedullary hematopoietic system, and increase peripheral leukocyte count in treatment on rats leukopenia model at *Zusanli* (ST-36) and *Dazhui* (DU-14) points of treatment [25].

As the aim of this study is focused on liver treatment, *Gan shu* (BL-18) point of acupuncture is chosen because this point is the main track toward the liver [26]. Four different dosages of energy were given to the sample by varying the irradiation times, namely, 30, 60, 90, and 120 sec. The repair level on liver dysfunction by carbofuran on male mice would be proven from the histology results and the scoring test.

Materials and Methods

Ethical approval

The study was approved by Animal Care and Use Committee of Veterinary Faculty, Universitas Airlangga. All variables have been considered in accordance with the Ethics Committee to ensure no discomfort or pain caused to the animals during sampling (2015/425-KE).

Animal characteristics

The animals used in this study were 30 male mice (*Mus musculus*) strain Balb/C, range of 10–14 weeks old for 25–30 gms range of weight. The distribution of samples was divided into three groups; Group C-L- (control group, no treatment), Group C+L- (only treated by carbofuran treatment), and Group C+L+ (treatment group, treated by

carbofuran and laser-puncture treatment). Each group and treatment had five replications.

Laser characterization

Laser characterization was carried out using grating spectrophotometer, optical detector, digital power meter, and digital thermometer. The form of diffraction pattern by grating spectrophotometer was used to determine the wavelength of laser. To determine the power of laser, the optical power is needed and connected to the digital power meter. The temperature of laser beam must not be above 37°C, so normal biological effect happens in tissues or cells.

Carbofuran treatment

The liver dysfunction by carbofuran was carried out by injection on mice (*M. musculus*) with a dosage of 1/12 LD50 or 1.3899 mg/kg weight of carbofuran [3].

Laser-puncture experimental set-up

The irradiation of laser-puncture using laser diode was done for 5 days with four different energy of dosages, namely, 0.5, 1.0, 1.5, and 2.0 Joule. The point of laser diode was pointed to the acupuncture point of BL-18 (*Gan shu*) with 0 mm of distance as shown in Figure 1.

Preparation of liver tissue

Three groups of samples, C-L-, C+L-, and C+L+, were dissected. The liver tissues were fixed in neutral formalin buffer solution for 24 h. After the fixation, a small piece of the liver was cut into 3–5 mm of thickness for each sample and then rinsed by water for 2 h and overnight. The fixed tissues were then dehydrated using ethanol 70%, 80%, 96%, and absolute alcohol. After dehydration process, tissues were soaked in xylene for clearing process. After that, cleared tissues were embedded into paraffin and cut into serial sections (4–5 µm of thickness). After deparaffinization and rehydration, tissues were then colored by hematoxylin and differentiated using flowing water. Tissues were then soaked in acid ethanol (1% HCl on 70% ethanol) and washed using distilled water.

Liver histopathology

The slices of liver cells were observed using microscope with 400 times of magnification. Each sample was sliced for two and observations were carried out in five fields of view around the liver central vein. The scoring of histology results was divided into four groups, which were from 0 to 3. Score 0 indicated that there is no inflammation cells and necrosis. Score 1 indicated less than 25% of damage in inflammatory cells and necrosis. Score 2 indicated 25%–50% of damage in inflammatory cells and necrosis. The last, Score 3 indicated more than 50% of damage in inflammatory cells and necrosis.

Statistical analysis

The data result of liver histopathology was analyzed from the Kruskal–Wallis Test and the Mann–Whitney *U* Test using Statistical Package for the Social Science (SPSS) program at $p < 0.05$.

Results

Laser characterization

The result of laser characterization showed that the wavelength of laser diode used as the laser-puncture is 650.01 ± 6.11 nm. The maximum power with distance of 0 mm of the laser is 16.99 ± 0.08 mW. Figure 2 shows the relation between the laser power and the distance from samples. As the laser could lead to an excessive heat, the temperature of laser beam should be measured. The laser beam temperature was measured by using a digital thermometer. The minimum temperature of the laser beam was $29^{\circ}\text{C} \pm 0^{\circ}\text{C}$ and the maximum temperature of laser beam showed was $30^{\circ}\text{C} \pm 1.99^{\circ}\text{C}$ for 120 sec. So, the laser is suitable to be used in this experiment because the laser beam temperature is below 37°C .

Anatomical histology test results

Anatomical histology observation results were obtained by observing microscopic slides of the liver of the experimental animals. Each group and treatment underwent five replications and five times observation for each replica. The histology of group C–L– is shown in Figure 3a. Samples of

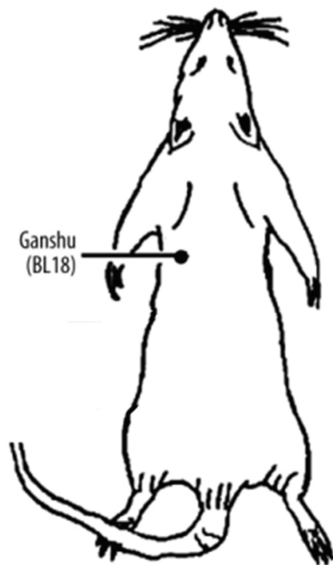


Figure 1. The point of laser diode at the acupuncture point of BL–18 (Gan shu) with 0 mm of distance.

the control groups of this study are the liver of mice without carbofuran injection and laser-puncture treatment. The histopathology score of group C–L– is 0.46 ± 0.11 . The score and statistical results of each group can be seen in Table 1. The statistical conclusions were compared to group C–L–.

The other group, group C+L–, was the samples that given carbofuran by injection without laser-puncture treatment. From statistical test by Mann–Whitney using SPSS, it is known that there was a significant difference between group C+L– and C–L–. Figure 3b shows the histology result of group C+L–.

The treatment group, group C+L+, was treated by carbofuran and laser-puncture treatment. Four different dosages of energy were given to the samples. The lowest dosage of energy used is 0.5 Joule with irradiation time of 30 sec. From the score result of each dosage, the best treatment was found when using 1.0 Joule; however, there were no significant differences on statistical analysis between 0.5 and 1 Joule treatments. The histology result of 0.5 Joule and 1.0 Joule of irradiation by laser-puncture treatments is presented in Figure 3c and d. The other dosages of energy used on this study were 1.5 and 2.0 Joule as shown in Figure 3e and f. The scoring test and statistical analysis on cell inflammation and necrosis could be seen in Figures 4 and 5. The same symbol of alphabet presented no significant difference on the Mann–Whitney Test.

Discussion

Healthy and sick bodies always carry out activities, in the form of mechanical vibrations (particle or molecular vibrations) and chemical reactions. In a healthy body, the

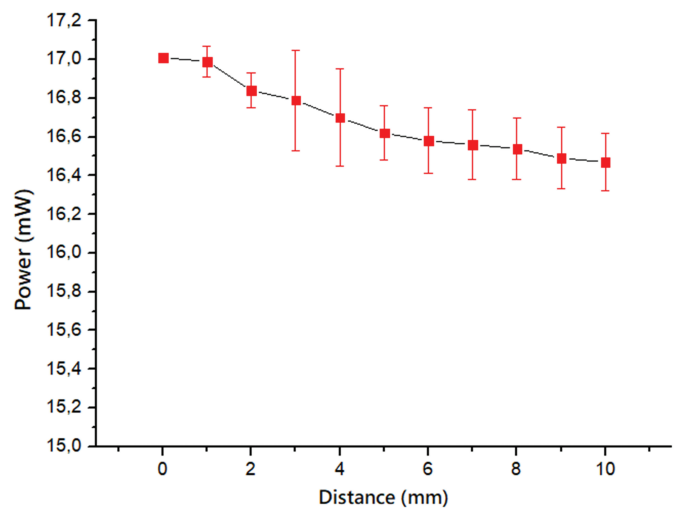


Figure 2. Laser beam characterization between power (mW) and distance (mm).

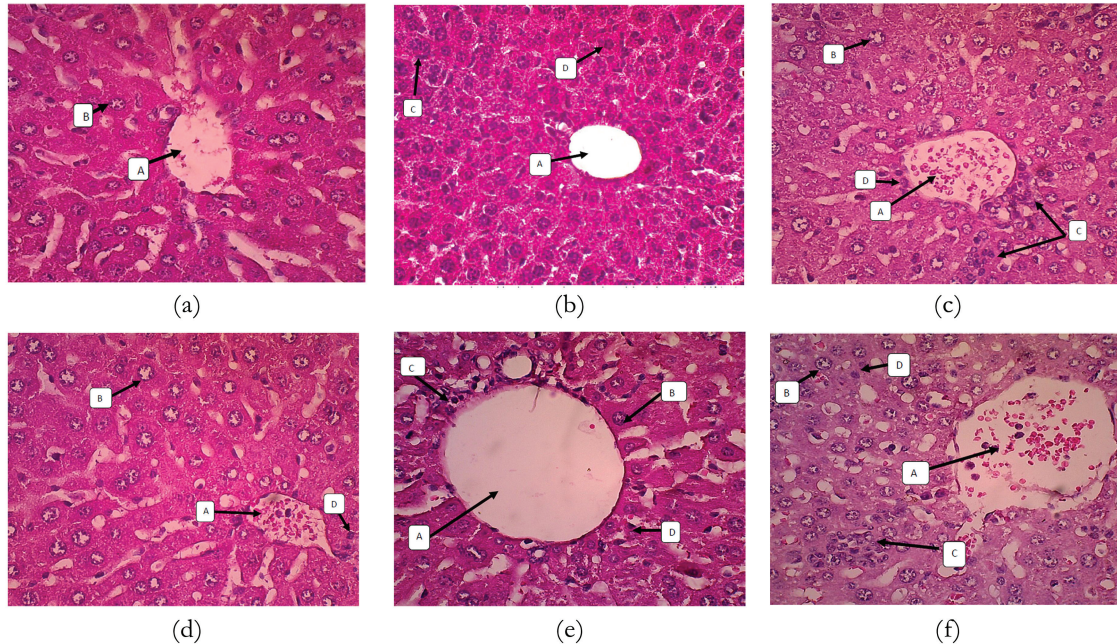


Figure 3. Histology test result: (a) group C-L-, (b) C+L-, (c) C+L+ 0.5 J, (d) C+L+ 1 J, (e) C+L+ 1.5 J, and (f) C+L+ 2 J. This figure showed the liver histology of the mice in negative control group, positive control group, the treated group with energy of 0.5 J, 1 J, 1.5 J, and 2 J. There were central vein (A), hepatocyte cells (B), inflammatory cells (C), and necrosis area (D).

Table 1. Conclusion table of analysis result.

Group	Dosage of Energy (Joule)	N	Average Value of Scoring		Mann-Whitney Test
			Inflammatory Cells	Necrosis	Significance
C-L-	0 ^(a)	5	0.14 ± 0.15	0.46 ± 0.11	-
C+L-	0 ^(b)	5	2.98 ± 0.04	2.76 ± 0.21	<i>p</i> = 0.008*
C+L+	0.5 ^(c)	5	0.92 ± 0.29	1.20 ± 0.29	<i>p</i> = 0.008*
	1.0 ^(c)	5	0.88 ± 0.28	0.72 ± 0.15	<i>p</i> = 0.008*
	1.5 ^(d)	5	2.62 ± 0.31	1.60 ± 0.07	<i>p</i> = 0.016*
	2.0 ^{(b)(d)}	5	2.74 ± 0.25	2.70 ± 0.23	<i>p</i> = 0.222

N = replication of sample. The same superscript showed no significant difference from the results of the Tukey test. *Significant.

vibrations of the organism have a very high level of regularity, resulting in a dynamic balance in the body. If the order of vibration of the organism decreases, the dynamic balance does not occur so that the body can be said to be in an unhealthy condition. Dynamic balance has a very important role in life, especially related to health (homeostasis) or material energy balance (physics). Balance loss creates a pathological state. Acupuncture is one of the traditional Chinese therapeutic methods [26,27]. This method of therapy is inexpensive and effective. Many research studies have been carried out so that currently there are a variety of tools used in acupuncture. One of the most popular therapeutic devices is Laser-puncture. The advantage of this

tool compared to the electronic stimulation (the most popular method of acupuncture therapy) is that it is not necessary to use a needle electrode. As it is known, people are reluctant to choose acupuncture therapy because of the fear of being punctured by a needle. The main advantage of Laser-puncture is that it does not cause pain to the patient, so this system is often performed on infants, children, and the elderly. Laser-puncture therapy is carried out by using a laser beam directed at certain acupuncture points to provide energy stimulation.

This study used laser diode as laser puncture to repair the liver cells dysfunction on mice. It is crucial to know the laser specification precisely. Laser characterization was

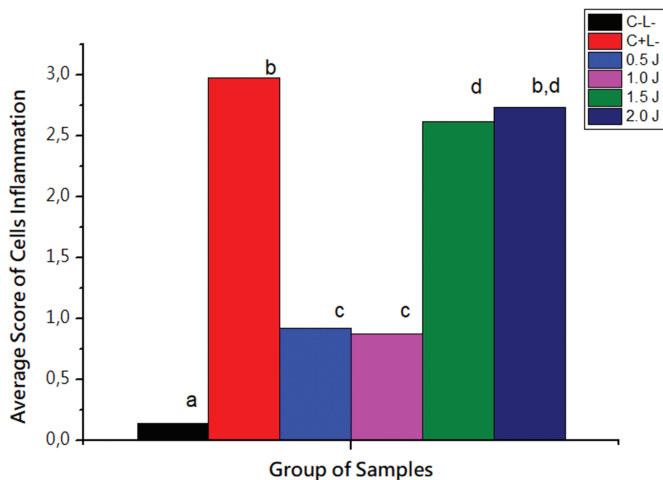


Figure 4. The average score result of cell inflammation histology. The result showed that the inflammatory cells in lower energy treated group was significantly different towards the positive control group based on Mann-Whitney Test. The different letter index indicated the significantly difference.

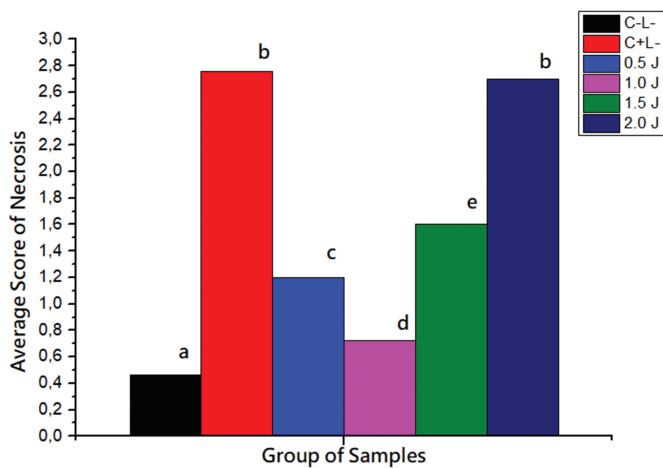


Figure 5. The average score result of necrosis histology. The result showed that the necrosis in lower energy treated group was significantly different toward the positive control group based on Mann-Whitney Test. The different letter index indicated the significantly difference.

carried out to determine the wavelength, the beam power, and the beam temperature. The red laser diode was chosen because its capability on penetration is better than other visible light laser diodes. This study used red laser diode with 650.01 ± 6.11 nm of wavelength. This laser was used as a laser-puncture which was also capable to transmit 17.01 mW of power with 0 mm distance from mice. The irradiation times used to achieve the custom dosage of energy are 30, 60, 90, and 120 sec with temperature of laser beam of 28°C–30°C. As the normal biological effect

on tissues and cells was at 37°C, the laser will not generate any harmful effects on liver tissues and cells but only generate photochemical reactions.

From the anatomical histology test result, carbofuran contamination causes cell inflammation and necrosis, which had proven by the group C+L- (Fig. 3b). Figure 3a shows the *M. musculus* normal liver cells, the closest score to these normal cells was obtained at 1.0 Joule treatment of laser-puncture. From observing the histology results, it was found that the 0.5 and 1.0 Joule laser-puncture treatments had more similar tissues to normal cells than the 1.5 and 2.0 Joule treatments. It could be told that the 0.5 and 1.0 Joule dosages of energy made repair on *M. musculus* liver cells.

The biomodulation effect of laser is on the wavelength of visible and near infrared spectrum [19,28]. This study used a laser with a wavelength of 650 nm because it had a good anti-inflammation effect in the clinical study (the synthesis modulation and cytokine pro and inflammation expression [28]. and animal model study, especially in the skeletal muscle [29,30]. The stimulation by using a laser with a wavelength of 650 nm in the animal model that has been induced by streptozotocin showed the activity of anti-hyperglycemic. The biomodulation therapy is one of the Low Level Laser Therapies (LLLTs). LLLT with nGaAlP 660 nm, spot size of 0.035 cm², output power of 20 mW, and power density of 0.571 W/cm² could modulate the balance between cytokine pro- and anti-inflammation, either systemic or peripheral [31,32].

The photon energy from laser could stimulate our body from acupuncture point, *Gan shu* or BL-18. This acupuncture point is the main track to the liver and it can help on the regulation of the liver. The photon that is given to the acupuncture point is to be absorbed, reflected, or scattered by the tissues. The important phenomenon is absorption; only cells with the same photon radiation frequency could absorb the photon energy from laser diode.

Adenosine Triphosphate (ATP) is released from mast cells by a physical stimulation: a putative early step in an activation of an acupuncture point [33]. The absorbed photon energy in tissue with the same photon radiation frequency will be forwarded until the liver tissues by depolarization form meridian system. This information will be read as chemical information by nucleus and will stimulate the liver cells' activity to generate the regeneration process, so it may accelerate the liver histopathology repair [34]. Meridian system, tissues that connected interior and exterior organs inside the body with body surface, is a point to achieve harmonic balance. The relation between acupuncture points and meridian system has been used in the medical diagnosis and traditional treatments.

Li et al. [22] reported that the effect of acupuncture is it can restore homeostasis under different pathological

conditions through activation of different reaction cascades in response to a pathological injury [22]. One of the acupuncture therapy equipment is the laser diode. This laser energy will activate a small network of acupuncture points (Acupoint Network), and this activation process will be propagated through meridians (Meridian Network). Information on acupuncture is reinforced by the cascade, and the nerve endocrine immune system (NEI) is activated through the body's own large meridian network. The NEI subsequently releases information effects to target organs through multilevel and multisystem and finally acts on the Disease Network to produce acupuncture effects.

Conclusion

It has been proven that Carbofuran contamination could lead to inflammation of cells and necrosis. Histology results and scoring test showed that the liver cells repair on laser diode treatment had the closest score to normal liver cells. The optimum energy dose of laser diode for liver cells repair is 1.0 Joule.

Acknowledgment

The author would like to say thank you to Ministry of Research, Technology and Higher Education with Grant number [No. 007/F1/PPK.2/Kp/V/2019].

Conflict of interests

The authors declare that there is no conflict of interests.

Authors' contribution

SDA, VSV, AFM, APP, and DW designed the study, interpreted the data, and drafted the manuscript. VSV and AFM were involved in collection of data and also contributed in manuscript preparation. SDA and APP took part in preparing and critical checking of this manuscript.

References

- [1] Hossen S, Prince MB, Tanvir EM, Chowdhury MAZ, Rahman A, Alam F, et al. *Ganoderma lucidum* and *Auricularia polytricha* mushrooms protect against carbofuran-induced toxicity in rats. *Evid Based Complement Alternat Med* 2018; 2018:6254929; <https://doi.org/10.1155/2018/6254929>
- [2] Jaiswal SK, Siddiqi NJ, Sharma B. Studies on the ameliorative effect of curcumin on carbofuran induced perturbations in the activity of lactate dehydrogenase in wistar rats. *Saudi J Biol Sci* 2018; 25(8):1585–92; <https://doi.org/10.1016/j.sjbs.2016.03.002>
- [3] Muhammad E, Widjiati L, Lita W, Yustinasari R, Ölümlü H. Brain cells death on infant mice (*Mus musculus*) caused by carbofuran exposure during the lactation period. *Kafkas Univ Vet Fak Derg* 2018; 24(6):845–52; <https://doi.org/10.9775/kvfd.2018.20045>
- [4] Hossen MS, Tanvir EM, Prince MB, Paul S, Saha M, Ali MY, et al. Protective mechanism of turmeric (*Curcuma longa*) on carbofuran-induced hematological and hepatic toxicities in a rat model. *Pharm Biol* 2017; 55(1):1937–45; <https://doi.org/10.1080/13880209.2017.1345951>
- [5] Samah M, Dalila B. Contribution to the study of the effect of one household pesticide used in Algeria, on the murine immune system. *Adv Env Biol* 2015; 9(8):192.
- [6] Vithanage M, Mayakaduwa SS, Herath I, Ok YS, Mohan D. Kinetics, thermodynamics and mechanistic studies of carbofuran removal using biochars from tea waste and rice husks. *Chemosphere* 2016; 150:781–9; <https://doi.org/10.1016/j.chemosphere.2015.11.002>
- [7] Yang JS, Park Y. Insecticide exposure and development of nonalcoholic fatty liver disease. *J Agric Food Chem* 2018; 66(39):10132–8; <https://doi.org/10.1021/acs.jafc.8b03177>
- [8] Carlos L, Benavides L, Alexander L, Pinilla C, Steffany J, López G, et al. Electrochemical biodegradation study of the carbofuran insecticide in soil. *Int J Appl Eng Res* 2018; 13(3):1776–83.
- [9] Chansuvarn W, Chansuvarn S. Distribution of residue carbofuran and glyphosate in soil and rice grain. *Appl Mech Mater* 2018; 879:118–24; <https://doi.org/10.4028/www.scientific.net/AMM.879.118>
- [10] Jaiswal SK, Sharma A, Gupta VK, Singh RK, Sharma, B. Curcumin mediated attenuation of carbofuran induced oxidative stress in rat brain. *Biochem Res Int* 2016; 2016:7637931; <https://doi.org/10.1155/2016/7637931>
- [11] Yumnam D, Dutta BK, Paul SB, Choudhury S. Alterations in the erythrocyte membrane and ultrastructural changes in the liver and kidney of albino mice exposed to fipronil. *Nat Environ Pollut Technol* 2017; 16(1):273–8.
- [12] Byrne CD, Targher G. NAFLD: a multisystem disease. *J Hepatol* 2015; 62(1 Suppl):S47–64; <https://doi.org/10.1016/j.jhep.2014.12.012>
- [13] Zegos P, Renner EL. Liver transplantation and non-alcoholic fatty liver disease. *World J Gastroenterol* 2014; 20(42):15532–8; <https://doi.org/10.3748/wjg.v20.i42.15532>
- [14] Astuti SD, Puspita PS, Putra AP, Zaidan AH, Fahmi MZ, Syahrom A, et al. The antifungal agent of silver nanoparticles activated by diode laser as light source to reduce *C. albicans* biofilms: an *in vitro* study. *Lasers Med Sci* 2019; 34(5):929–37; <https://doi.org/10.1007/s10103-018-2677-4>
- [15] Astuti SD, Arifianto D, Drantantiyas NDG, Nasution AMT, Abdurachman. Efficacy of CNC-diode laser combine with chlorophylls to eliminate *Staphylococcus aureus* biofilm *IEEE* 2016; 57–61; <https://doi.org/10.1109/ISSIMM.2016.7803722>
- [16] Astuti SD, Zaidan AH, Setiawati EM, Suharningsih. Chlorophyll mediated photodynamic inactivation of blue laser on *Streptococcus mutans*. *AIP Conf Proc* 2016; 1718(1):120001; <https://doi.org/10.1063/1.4943353>
- [17] Niemz MH. *Laser-Tissue Interactions, Fundamentals and Applications*. 3rd edition, Springer-Verlag, Berlin Heidelberg, Heidelberg, 2007.
- [18] Caccianiga G, Baldoni M, Ghisalberti CA, Paiusco A. A Preliminary *in vitro* study on the efficacy of high-power photodynamic therapy (HLLT): comparison between pulsed diode lasers and superpulsed diode lasers and impact of hydrogen peroxide with controlled stabilization. *BioMed Res Int* 2016; 1386158; <https://doi.org/10.1155/2016/1386158>
- [19] Astuti SD, Prasaja BI, Prijo TA. An *in vivo* photodynamic therapy with diode laser to cell activation of kidney dysfunction. *J Phys Conf Ser* 2017; 85:12038; <https://doi.org/10.1088/1742-6596/853/1/1012038>
- [20] Setiawati EM, Lestari VP, Astuti SD. Comparison of antibacterial efficacy of photodynamic therapy and doxycycline on *Aggregatibacter Actinomycetemcomitans*. *Afr J Infect Dis* 2018; 12(1 Suppl):95–103; <https://doi.org/10.2101/Ajid.12v1S.14>
- [21] Asnaashari M, Mojahedi SM, Asadi Z, Azari-Marhabi S, Maleki A. A comparison of the antibacterial activity of the two methods of photodynamic therapy (using diode laser 810 nm and LED lamp 630 nm) against *Enterococcus faecalis* in extracted human anterior

- teeth. *Photodiagn Photodyn Ther* 2016; 13:233–7; <https://doi.org/10.1016/j.pdpdt.2015.07.171>
- [22] Li NC, Li MY, Chen B, Guo Y. A new perspective of acupuncture: the interaction among three networks leads to neutralization. *Evid Based Complement Alternat Med* 2019; 2326867; <https://doi.org/10.1155/2019/2326867>
- [23] Moskvina SV. Low-Level laser therapy in Russia: history, science and practice. *J Lasers Med Sci* 2017; 8(2):56–65; <https://doi.org/10.15171/jlms.2017.11>
- [24] de Souza RC, Pansini M, Arruda G, Valente C, Brioschi ML. Laser acupuncture causes thermal changes in small intestine meridian pathway. *Lasers Med Sci* 2016; 31(8):1645–9; <https://doi.org/10.1007/s10103-016-2032-6>
- [25] Liu L, Zhao L, Cheng K, Deng H, Guo M, Wei J, et al. Examination of the cellular mechanisms of leukocyte elevation by 10.6 μm and 650 nm laser acupuncture-moxibustion. *Lasers Med Sci* 2019; 34(2):263–71; <https://doi.org/10.1007/s10103-018-2581-y>
- [26] Kim YJ. Acupuncture management for sleep disturbances patients: a case report with inflammatory cytokine levels evaluation. *J Acupunct Meridian Stud* 2019; <https://doi.org/10.1016/j.jams.2018.05.008>
- [27] Moudgil KD, Berman BM. Traditional Chinese medicine: potential for clinical treatment of rheumatoid arthritis. *Expert Rev Clin Immunol*, England 2014; 10(7):819–22; <https://doi.org/10.1586/1744666X.2014.917963>
- [28] Pires D, Xavier M, Araujo T, Silva JA Jr, Aimbire F, Albertini R. Low-level laser therapy (LLLT; 780 nm) acts differently on mRNA expression of anti- and pro-inflammatory mediators in an experimental model of collagenase-induced tendinitis in rat. *Lasers Med Sci* 2011; 26(1):85–94; <https://doi.org/10.1007/s10103-010-0811-z>
- [29] Calderin S, Garcia-Nunez JA, Gomez C. Short-term clinical and osteoimmunological effects of scaling and root planning complemented by simple or repeated laser phototherapy in chronic periodontitis. *Lasers Med Sci* 2012; 28(1):157–66.
- [30] Mesquita-Ferrari RA, Martins MD, Silva JA, da Silva TD, Piovesan RF, Pavesi VC, et al. Effects of low-level laser therapy on expression of TNF-alpha and TGF-beta in skeletal muscle during the repair process. *Lasers Med Sci* 2011; 26(3):335–40; <https://doi.org/10.1007/s10103-010-0850-5>
- [31] Hentschke VS, Jaenisch RB, Schmeing LA, Cavinato PR, Xavier LL, Lago PD. Low-level laser therapy improves the inflammatory profile of rats with heart failure. *Lasers Med Sci* 2013; 28(3):1007–16; <https://doi.org/10.1007/s10103-012-1190-4>
- [32] Jaenisch RB, Hentschke VS, Quagliotto E, Cavinato PR, Schmeing LA, Xavier LL, et al. Respiratory muscle training improves hemodynamics, autonomic function, baroreceptor sensitivity, and respiratory mechanics in rats with heart failure. *J Appl Physiol* 2011; 111(6):1664–70 <https://doi.org/10.1152/japplphysiol.01245.2010>
- [33] Wang L, Sikora J, Hu L, Shen X, Grygorczyk R, Schwarz W. ATP release from mast cells by physical stimulation: a putative early step in activation of acupuncture points. *Evid Based Complement Alternat Med* 2013; 350949; <https://doi.org/10.1155/2013/350949>
- [34] Saleh R, Merghani BH, Awadin W. Effect of high fructose administration on histopathology of kidney, heart and aorta of rats. *J Adv Vet Anim Res* 2017; 4(1):71–9; <http://doi.org/10.5455/javar.2017.d193>