

ORIGINAL ARTICLE

Comparative morphological interpretations on the bones of the pelvic limb of New Zealand rabbit (*Oryctolagus cuniculus*) and domestic cat (*Felis domestica*)

Hanaa Mohamed El-Ghazali, Eman Ismail El-behery

Department of Anatomy and Embryology, Faculty of Veterinary Medicine, Zagazig University, Zagazig 44511, Egypt

ABSTRACT

Objective: Regarding the displaying of the main differences between the pelvic limb of rabbit and cat.

Materials and methods: Our work was performed on 10 New Zealand rabbits (*Oryctolagus cuniculus*) and domestic cats (*Felis domestica*) with variable ages and of both sexes. After weighing of the animals, sedation, and anesthesia, the animals were examined radiographically. The bones of the pelvic limb were prepared, measured for its length/cm then described and compared.

Results: The iliac tuberosity and the conversion of the acetabular notch into foramen were characteristics of *Os coxae* of the rabbit. The intertrochanteric crest was detected on the femur of the cat. In the rabbit, the leg interosseous space was located in the proximal third of this region while in the cat, it was extended along its length. The first metatarsal was undeveloped in the cat but was absent in the rabbit so metatarsal were four in the rabbit and five in the cat. The digits of the pelvic limbs in both animals were four in number. The distal sesamoid was single, transversely situated, and shuttle-shaped in rabbit but it was absent in cat.

Conclusion: So, the chief points of variation between the pelvic limb bones of rabbit and cat enabled us to keep away the commercial fraud and facilitated their use as an animal model for education purposes.

ARTICLE HISTORY

Received June 06, 2018
Revised August 10, 2018
Accepted August 12, 2018
Published November 09, 2018

KEYWORDS

Acetabulum; fabellae;
intertrochanteric crest; ungicular
process



This is an Open Access article distributed under the terms of the Creative Commons Attribution 4.0 Licence (<http://creativecommons.org/licenses/by/4.0>)

Introduction

Rabbit is efficiently feasible to be used as a source of meat and for the fur industry. Due to the high fertility, short generation period, little size, low cost of rabbit, and it is being used in the production of antibodies, Okerman [1] considered rabbit as a perfect laboratory animal. The rabbit is used for recognition of some anomalies and diseases as an excellent experimental clinico-anatomical example of humans and animals [2].

In mole-rat (*Spalax leucodon* Nordmann), the acetabulum is deep and there is a little foramen instead of the acetabular notch. The greater trochanter of the femur is separated from the head by a notch [3]. The fibula and tibia of rabbit are fused but in the cat they are separated [4]. In marmoset (*Callithrix jacchus*), the tarsus contains seven tarsal bones and no distal sesamoid bones are present at the plantar sides of the distal interphalangeal joints [5]. In

the cat, there are seven tarsal bones, four complete metatarsals with four digits [6]. In the rabbit, the plantar surface of the hind limb from the tarsus distally was in contact with the ground at rest [7].

For the above-mentioned reasons, our research focuses on the most important differences between the bones of the pelvic limb of rabbits and cats to keep away from the commercial fraud where rabbits are used as human food in our country. Also, we hope to facilitate the process of anatomy education by using rabbits and cats as animal models.

Materials and methods

Ethical statement

All obtained animals in this paper were managed according to the Institutional Animal Care and the Research

Correspondence Hanaa Mohamed El-Ghazali ✉ dr_h1980@hotmail.com 📧 Department of Anatomy and Embryology, Faculty of Veterinary Medicine, Zagazig University, Zagazig 44511, Egypt.

How to cite: El-Ghazali HM, El-behery EI. Comparative morphological interpretations on the bones of the pelvic limb of New Zealand rabbit (*Oryctolagus cuniculus*) and domestic cat (*Felis domestica*). J Adv Vet Anim Res 2018; 5(4):410–9.

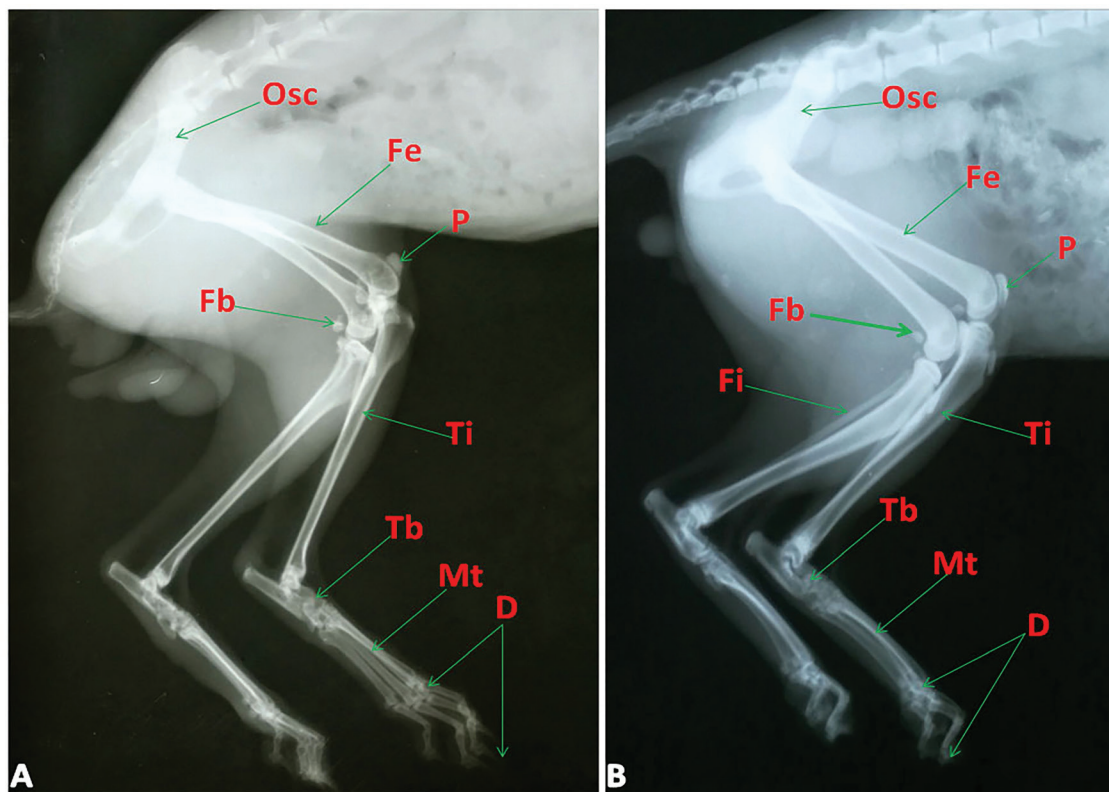


Figure 1. Radiographs of rabbit's (A) and cat's (B) pelvic limbs (lateral view) showing Osc: Os coxae, Fe: Femur, P: Patella, Fb: Fabellae, Ti: Tibia, Fi: Fibula, Tb: Tarsal bones, Mt: Metatarsal bones and D: Digit.

Ethics Committee of the Zagazig University, Egypt (ZU-IACUC/2/F/12/2018).

Number of animals and site of collection

The current research was accomplished on 10 healthy adults New Zealand rabbits (*Oryctolagus cuniculus*) and domestic cats (*Felis domestica*) with variable ages and of both sexes. The weight of animals was about 2.5–3.5 kg. The rabbits were obtained from the animal laboratory house in Faculty of Veterinary Medicine, Zagazig University, Egypt. The cats were bought from pet house in Zagazig city, Sharkia Governorate, Egypt.

Procedures

The sedation and anesthesia occurred with 3 mg/kg xylazine i.v followed by 3 mg/kg ketamine i.v injection through the ear vein and with 1 mg/kg of i.m. xylazine then followed by 5 mg/kg of i.m. ketamine for rabbits and cats, respectively [8]. By using the digital scale, the animals were weighted. For the radiographical examination, two animals of both species were prepared and inspected in the Department of Surgery, Anesthesiology and Radiation, Faculty of Veterinary Medicine, Zagazig University. The animal exsanguinations were carried out

through the common carotid artery under complete anesthesia. After evisceration and dissection of pelvic limbs from the trunk and removal of the skin and muscles carefully, the bony preparations were performed according to Onwuama et al. [9].

The comparison between the same bones of the pelvic limb in both species was applied and focused on several points as gross morphology, length/cm, and numbers. The measurements were obtained using graduated tape. By using a digital camera with resolution (16.1 megapixels, Sony DSC-W690, 36v and 10x optical zoom), the bones were photographed.

Data analysis

The mean \pm standard deviation (SD) of the bones measured data were estimated by using the SPSS software program (version 16.0; Chicago, USA).

The used anatomical nomenclature was based on Nomina Anatomica Veterinaria [10] whenever possible.

Results

The pelvic limbs of both animals were formed of Os coxae, femur, tibia and fibula, tarsal and metatarsal bones and

digits associated with the patella, fabellae, and sesamoid bones (Fig. 1A and B).

Os coxae

In rabbit and cat, it was formed from the union of three bones; ilium, ischium, and pubis which they shared in the formation of the acetabulum. The latter was formed of two portions; articular and non-articular parts [acetabular fossa (Fossa acetabuli)] (Fig. 2A and B). The articular part was crescentic in shape in rabbit and cat. In the rabbit, the ends of the articular part met each other caudomedially above the acetabular notch (Incisura acetabuli) converting it into a foramen (Fig. 2A).

In the rabbit, the wing of the ilium was shovel-like while in the cat it was spatula shape (deep concave gluteal surface and flat pelvic one). The gluteal surface (Facies glutea) in rabbit was marked by a thick ridge [gluteal line (Lineae gluteae)] (Fig. 2A) while in cat it was ventrolateral and began from the coxal tuber and extended parallel to the lateral border (Fig. 2B). In the rabbit, the line ended at the iliac tuberosity (Fig. 2A). The pelvic surface had a C-shaped auricular surface (Facies auricularis) for articulation with the wing of the sacrum in cat and rabbit (Fig. 2C and D). The iliac crest (Crista iliaca) was thin in rabbit and thick in the cat (Fig. 2C and D). The lateral and medial borders were thin edges and transparent in rabbit while in the cat the medial one was thick. The sacral tuber (Tuber sacrale) was thick while the coxal (Tuber coxae) one was thin in rabbit and cat (Fig. 2A–D). The body had medial, lateral, and ventrolateral surfaces and medial, lateral and ventral borders in the rabbit. On the other hand, the body in the cat had medial and lateral surfaces and lateral and medial borders. The pelvic surface carried faint obturator groove (Sulcus obturatorius) in both animals (Fig. 2C and D). The lateral border of the rabbit bears truncated iliac tuberosity (Fig. 2A). The medial border shared in the formation of a large portion of the greater ischiatic notch (Fig. 2C). The ventral border in rabbit had an iliopectinal line while the lateral one of cat continued with this line and born a psoas tubercle (Fig. 2D).

The ischium was quadrilateral in shape with pubic and acetabular branches. The pubic branch met its fellow at the pelvic symphysis and reached the symphyseal branch of the pubis (Fig. 2C and D). The acetabular branch was shared in the formation of the acetabulum and dorsal ischiatic spine (Spina ischiadica). The latter spine was thin beak-like in rabbit and low everted in the cat (Fig. 2C and D).

The surfaces of the ischium were pelvic and ventral which were thin and smooth. The ischial borders were medial (symphyseal), cranial, caudal, and lateral. The latter borders formed the pelvic symphysis, the caudal boundary of the obturator foramen (Foramen obturatum), ischial arch, and lesser ischiatic notch, respectively

(Fig. 2A–D). The ischial arch was deeply inverted v-shape in rabbit whereas it was a shallow concave one in the cat (Fig. 2C and D). The ischium had four angles, the caudolateral one formed the ischiatic tuber (Tuber ischiadicum) which it had lateral tuberosity in rabbit (Fig. 2C).

The pubis was inverted L-shape. It had acetabular and symphyseal branches. The pubis had pelvic and ventral surfaces and cranial, caudal, and medial borders. The pecten of the pubis carried clear pubic tubercle in rabbit and indistinct one in cat medially. The iliopectineal eminence in rabbit was clear and connected laterally to the iliopectineal line but in cat, it was indistinct (Fig. 2C and D). In both animals, the caudal border was formed the cranial boundary of the obturator foramen and in rabbit, it carried small projection medially (Fig. 2C). The obturator foramen in the rabbit was large oval with a thin sharp medial boundary while in cat it was elliptical with small thick medial boundary (Fig. 2A and B).

Femur

There was a great difference in the position of the femur between the two animals as it was located horizontally in rabbit and oblique cranioventral in the cat (Fig. 1A and B). The relative length of the femur was 9.040 ± 0.7427 cm in rabbit and 11.440 ± 0.3169 cm in the cat. In the rabbit, the body had two surfaces and two borders while in cat, it was cylindrical with four surfaces and two borders (Fig. 3A and B). In the rabbit, the dorsal surface was convex and the ventral one was concave longitudinally (Fig. 3A and C). The two surfaces were smooth and rounded from side to side. In the cat, the nutrient foramen was present just above the middle of the caudal surface (Fig. 3D).

The lesser trochanter (Trochanteric minor) in rabbit (Fig. 3A, C, and E) was in the proximal third of the medial border and just distal to it, the nutrient foramen was present (Fig. 3E). The former was a triangle in shape with the tooth-like apex (Fig. 3C and E) while in cat, it was large rounded in shape (Fig. 3D). In the rabbit, the third trochanter (Trochanteric tertius) (Fig. 3A, C, E, and F) was present at the same level of the lesser trochanter even as it was absent in cat (Fig. 3B, D, and G).

The proximal extremity had a hemispherical head and rounded one in rabbit and cat, respectively (Fig. 3F and G). Fovea capitis was a small circular pit in rabbit (Fig. 3F) while it was large in the cat (Fig. 3G). Laterally, there was the greater trochanter (Trochanteric major) which was divided in both animals. In the rabbit, it was elevated than the level of the head and its caudal part was bent medially but in cat, it was at the same level (Fig. 3F and G). The trochanteric ridge was bounded the trochanteric fossa (Fig. 3C). In the cat, the intertrochanteric crest was connected between the greater trochanter and the lesser one (Fig. 3D).

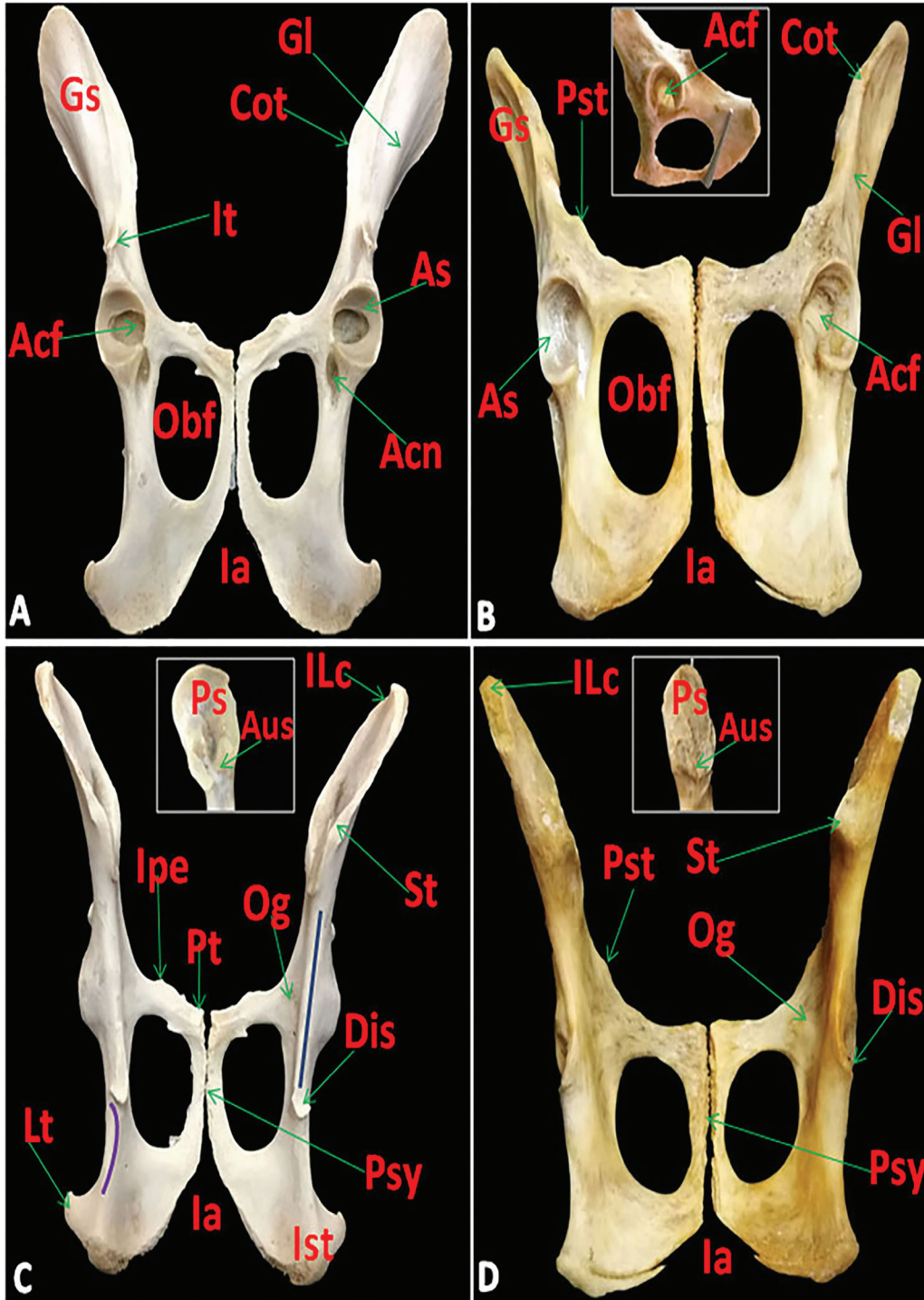


Figure 2. Photomacrographs of Os coxae of rabbit (A) and cat (B) (ventral view), Os coxae of rabbit (C) and cat (D) (caudodorsal view) with the insert showing pelvic surface of wing of rabbit's and cat's ilium showing Gs: Gluteal surface, Gl: Gluteal line, It: Iliac tuberosity, ILc: Iliac crest, As: Acetabular articular surface, Acf: Acetabular fossa, Acn: Acetabular notch converted into foramen, Cot: Coxal tuber, St: Sacral tuber, Ps: Pelvic surface, Aus: Auricular surface, Pt: Pubic tubercle, Ipe: Iliopectineal eminence, Pst: Psoas tubercle, Of: Obturator foramen, Og: Obturator groove, Dis: Dorsal ischiatic spine, Blue line: Greater ischiatic notch, purple line: Lesser ischiatic notch, Ia: Ischial arch, Ist: Ischiatic tuber, Lt: Lateral tuberosity, and Psy: Pelvic symphysis.

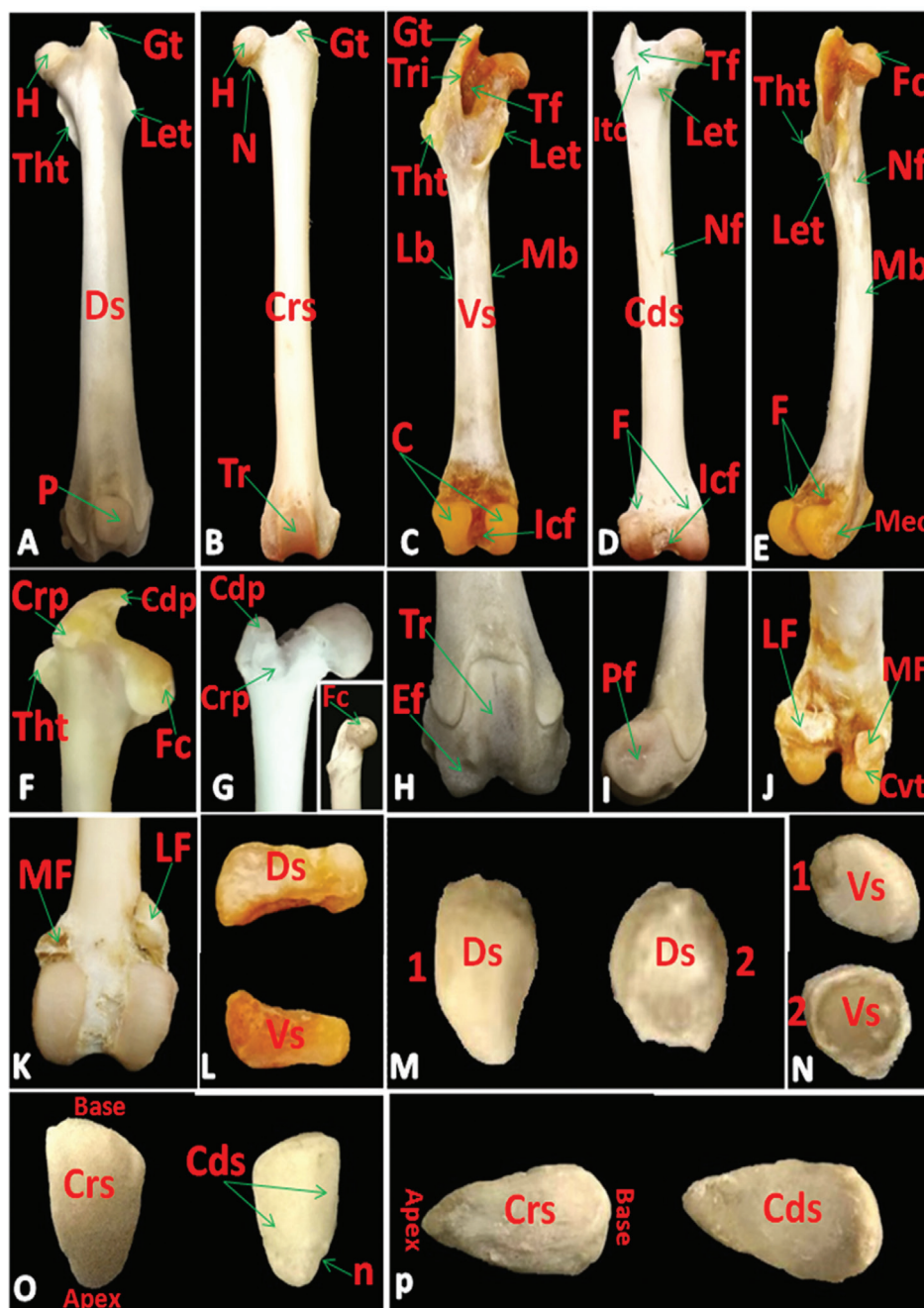


Figure 3. Photomicrographs of femur of rabbit (A) (dorsal view), femur of cat (B) (cranial view), femur of rabbit (C) (ventral view), femur of cat (D) (caudal view), femur of rabbit (E) (Medial view), proximal extremity of femur of rabbit (F) and cat (G) (cranial view) with the insert showing fovea capitis on the head (medial view), distal extremity of femur of rabbit (H) (cranial), (I) (lateral) and (J) (caudodorsal) views, distal extremity of femur of cat (K)(caudal view), lateral fabella of rabbit (L) (dorsal and ventral views), lateral (1) and medial (2) fabella of cat (M) (dorsal) and (N) (ventral) views, patella of rabbit (O) and cat (P) (cranial and caudal views) showing Gt: Greater trochanter, Let: Lesser trochanter, Tht: Third trochanter, H: Head, N: Neck, Crs: Cranial, Cds: Caudal, Ds: Dorsal and Vs: Ventral surfaces, Mb: Medial and Lb: lateral borders, P: Patella articulated with trochlea, Tr: Trochlea, Tri: Trochanteric ridge, Tf: Trochanteric fossa, Itc: Intertrochanteric crest, C: Condyles, Icf: Intercondyloid fossa, Nf: Nutrient foramen, F: Facets for fabellae, Fc: Fovea capitis, Mec: Medial epicondyle, Crp and Cdp: Cranial and caudal parts of the greater trochanter, Ef: Extensor fossa, Pf: Popliteal fossa, Lf: Lateral and Mf: Medial fabellae, Ct: Caudiventral tubercle and n: notch on the lateral border of patella.

The distal extremity was composed of the trochlea dorsally in rabbit and cranially in the cat. Also, two condyles and epicondyles (lateral and medial) present ventrally in rabbit and caudally in the cat (Fig. 3B–E). There was deeply intercondyloid fossa (Fossa intercondylaris) (Fig. 3C and D) and faint extensor (Fossa extensoria), one in rabbit (Fig. 3H) whilst the extensor fossa in the cat was indistinct. The popliteal fossa (Fossa m. poplitei) (Fig. 3I) was present on lateral epicondyle. There was a faint smooth area above the two condyles for articulation with lateral and medial fabellae in both animals (Fig. 3D, E, J, and K).

Patella and fabellae

In the rabbit, the lateral fabella was elongated, quadrilateral with large, broad medial part, and small tuberosity lateral one. It had two surfaces; dorsal irregular and ventral smooth saddle shaped (Fig. 3L). In the cat, the lateral fabella was an irregular triangle in shape with convex dorsal surface and flat ventral one (Fig. 3M and N). The medial fabella in rabbit and cat was rounded in shape. It had a tubercle caudoventrally in rabbit while in cat had a convex dorsal surface and concave smooth ventral one (Fig. 3J, M, and N).

In rabbit and cat, the patella was pyramidal in shape. Its distal apex was more rounded in rabbit and pointed in cat while the proximal base was broad in rabbit and rounded in the cat. It had a cranial convex rough non-articular surface and smooth caudal articular one. The latter surface was divided by a ridge into a small lateral part and large medial one in rabbit but in cat it was concave. The lateral border had a small notch distally in rabbit even as in cat, the two borders were rounded (Fig. 3O and P).

Tibia and fibula

In the rabbit, the two bones were fused with each other in the distal two-thirds while in the cat, the bones were completely separated along its length (Fig. 4A–E). Tibia of rabbit was about 10.040 ± 1.0102 cm length while in cat it was about 11.580 ± 0.3765 cm. In the rabbit, the body of the tibia was three-sided proximally and flattened distally (Fig. 4A and C); moreover, in cat, it was three-sided along its length (Fig. 4B and D). The cranial border formed a sharp tibial crest, which was indistinct distally in the cat. The crest was thin sharp in rabbit while thick in cat and it was slightly curved laterally (Fig. 4A and B). The interosseous space present proximally in the leg region of rabbit but in cat, it extended along that region (Fig. 4A and E). In the rabbit, the popliteal line (Linea m. poplitei) was clearly present on the proximal part of the caudal surface (Fig. 4C), furthermore, in the cat, this line was absent (Fig. 4D). In the cat, the nutrient foramen was present on the proximal third of the caudal surface toward the lateral border (Fig. 4D).

In the two animals, the proximal extremity consisted of two condyles (lateral and medial) and in between lateral and medial intercondyloid eminence (Fig. 4C, D, and F). Also, there were clear caudal intercondyloid fossa and faint cranial, one in rabbit while the latter fossa was clear in the cat (Fig. 4G). The tibial tuberosity (Tuberositas tibiae) was undivided and placed anteriorly on the proximal extremity and from it, the tibial crest was extended (Fig. 4A and B).

The distal extremity (Fig. 4H) had two flat facets separated by a groove for articulation with the trochlea of tibial tarsal bone whereas, in cat, it had two grooves separated by a ridge. The medial malleolus (Malleolus medialis) was small in rabbit and large in the cat. The lateral malleolus (Malleolus lateralis) was a large pointed projection which represented the distal extremity of the fibula in the rabbit (Fig. 4H).

In the rabbit, fibula was reduced long bone (Fig. 4A and C) but in cat, it was complete long bone (Fig. 4E, I, and J) with mean length about 4.980 ± 0.4917 cm in rabbit and 10.780 ± 0.3676 cm in the cat. The head (Caput fibulae) articulated with facet just distal to the lateral condyle of the tibia in rabbit and two facets in the cat. The head appeared divided by a groove into two triangular areas caudolaterally (Fig. 4J). Distally, the lateral malleolus appeared grooved and carried two projections caudolaterally (Fig. 4I).

Tarsal bones

The tarsal bones (Ossa tarsi) were six and seven short bones in rabbit (Fig. 5A) and cat (Fig. 5B; Table 1), respectively. They were arranged in proximal and distal rows and the central tarsal bone was in-between. The proximal row included the tibial (Talus) medially and the fibular (Calcaneus) laterally. The fibular tarsal bone was cylindrical and its length was twice the tibial tarsal bone. The central tarsal bone (Os tarsi centrale) was nearly cuboid in shape with a caudomedial process in rabbit (Fig. 5A) while in cat it was oval in outlines with a concave proximal surface (Fig. 5B and C).

In the rabbit, the distal row had three bones; the second, third, and fourth tarsal bones from medial to lateral. The fourth tarsal was the largest and had a groove on the palmar surface (Fig. 5A). In the cat, this row contained four bones. The first and fourth bones were similar quadrilateral in shape while the first was smaller in size. The second was somewhat crescentic and flattened but the third was pyramidal in shape (Fig. 5B and C).

Metatarsals and digits

There was four metatarsal (Ossa metatarsalia) in rabbit and five in the cat (Table 1) which they were well developed from the second to the fifth. The first in the cat was undeveloped and absent in rabbit. The metatarsals were

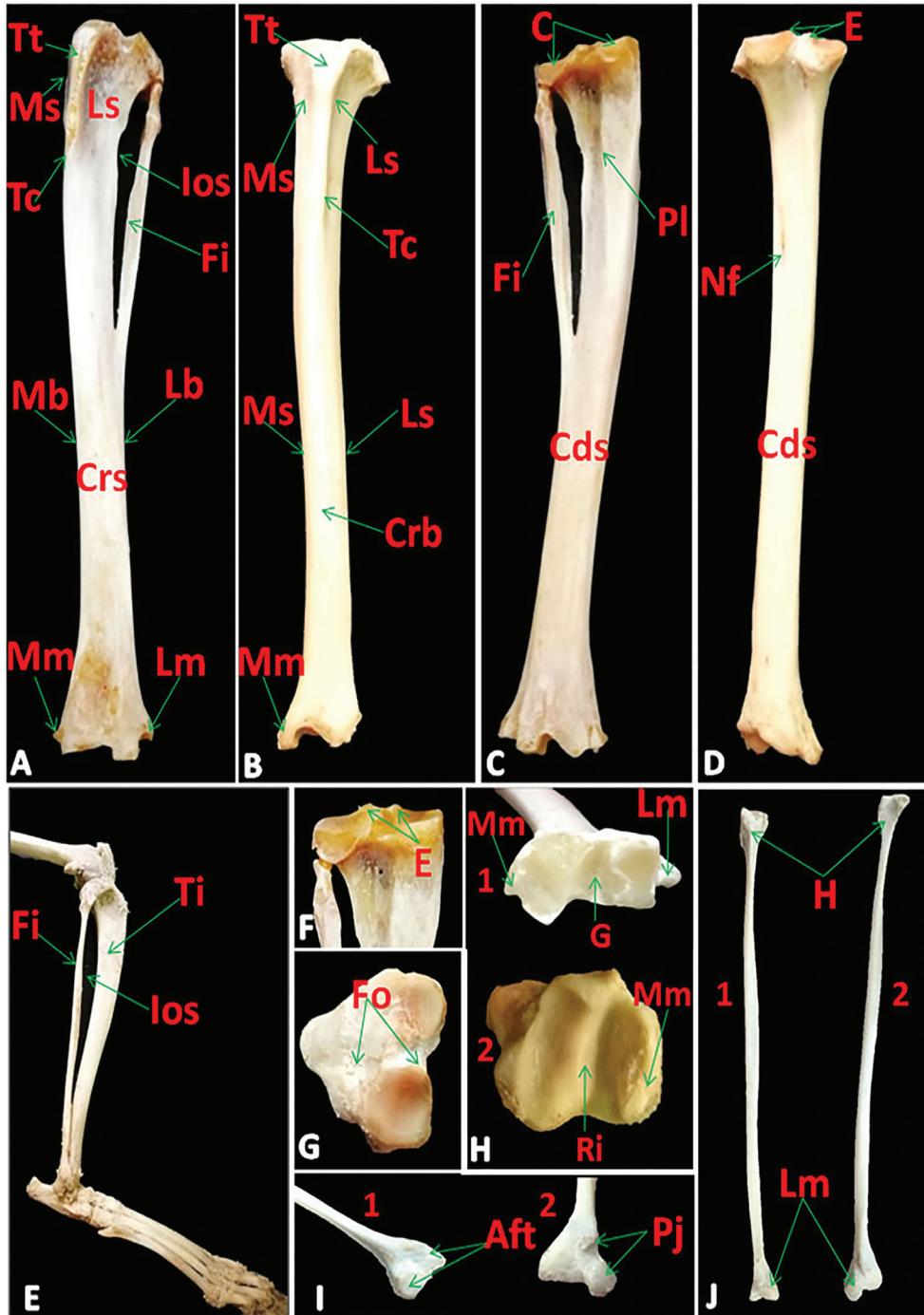


Figure 4. Photomacrographs of tibia and fibula of rabbit (A) and tibia of cat (B) (cranial view), tibia and fibula of rabbit (C) and tibia of cat (D) (caudal view), tibia and fibula of cat (E) (lateral view), proximal extremities of tibia of rabbit (F) (caudal view) and cat (G) (dorsal view), distal extremities of tibia of (1): rabbit and (2): cat (H) (ventral view), lateral malleolus of cat (I) (1:cranial and 2: caudal views) and fibula of cat (J) (1:cranial and 2:caudal views) showing Tt: Tibial tuberosity, Tc: Tibial crest, Ios: Interosseous space, Ti: Tibia, Fi: Fibula, Lm: Lateral and Mm: Medial malleolae, C: Condyles, Pl: Popliteal line, Ls: Lateral, Ms: Medial, Crs: Cranial and Cds: Caudal surfaces, Lb: Lateral, Mb: Medial and Crb: cranial borders, Nf: Nutrient foramen, E: Eminences, Fo: Two fossae, G: Groove, Ri: Ridge, H: Head, Pj: Two projections and Aft: Two facets for articulation with tibia.

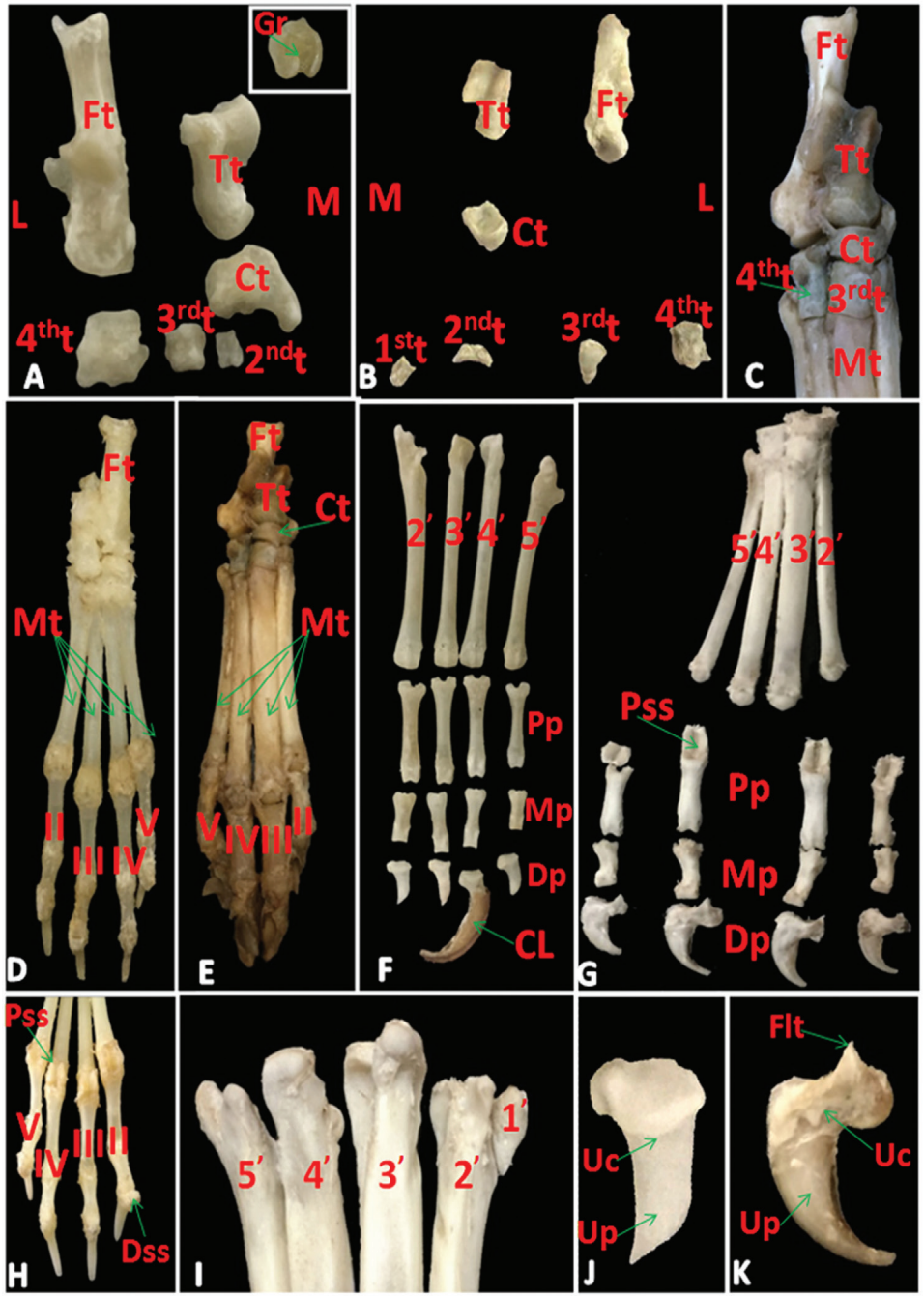


Figure 5. Photomacrographs of tarsal bones of rabbit (A) and cat (B) (craniodorsal view) with the insert showing the palmar surface of the 4th tarsal bone, tarsal and metatarsal bones of cat (C) (cranial view), pes region of rabbit (D) and cat (E) (dorsal view), metatarsal and digits of rabbit (F) and cat (G) (dorsolateral view), digits and sesamoid bones of rabbit (H) (palmar view), proximal extremity of metatarsal bones of cat (I) (dorsal view), distal phalanx of rabbit (J) and cat (K) (lateral view) showing L: lateral and M: Medial sides, Ft: Fibular, Tt: Tibial, Ct: Central, 1st: First, 2nd: Second, 3rd: Third and 4th: Fourth tarsal bones, Gr: groove on the palmar surface of 4th, Mt: Metatarsal bones, 1', 2', 3', 4', and 5': First, second, third, fourth, and fifth metatarsal bones, II, III, IV, and V: Second, third, fourth, and fifth digits, Cl: Claw, Flt: Flexor tubercle, Uc: Unguicular crest, Up: Unguicular process, Pp: Proximal, Mp: Middle and Dp: Distal phalanges, Pss: Proximal, and Dss: Distal sesamoid bones.

Table 1. Elucidate the numbers of the bones in pes region of rabbits and cats.

Species	Rabbit	Cat
Bones		
Tarsal (from Medial. to lateral)	6	7
1st row→	2 (Tibial and Fibular.T.B)	2 (Tibial and Fibular.T.B)
central	Central T.B	Central T.B
2nd row→	II, III, and IV	I, II, III, and IV
Metatarsal (from Medial to lateral)	4	5
	II, III, IV, and V	II, III, IV, and V
	I → absent	I → reduced
Digits	4	4
	I→ absent	I→ absent
	II, III, IV, and V→ each carry three phalanges	II, III, IV, and V→ each carry three phalanges
Sesamoid bones		
Proximal	8	8
	2 for each digit	2 for each digit
Distal	4	Absent
	1 for each digit	

similar to the metacarpals as long bones, had two extremities and shaft but extremely exceed in their size (Fig. 5D–I).

In the two animals, the digits (*Ossa digitorum pedis*) were four in number (Table 1). In the rabbit, the fifth digit was shortest (Fig. 5F). The second and fifth digits were the shortest and the third and fourth digits were the longest in the cat (Fig. 5G). In two animals, the third phalanx was enclosed in claw and triangular in shape with base proximally and apex distally (unguicular process). The latter process was broad in rabbit (Fig. 5J) and more pointed in the cat (Fig. 5K). The relative length of the pes region was about 10.680 ± 1.1924 cm and 11.160 ± 0.4377 cm in rabbit and cat, respectively.

Sesamoid bones

There were three sesamoids in rabbit and two in the cat for each digit (Fig. 5G and H; Table 1). The proximal sesamoids (*Ossa sesamoidea proximalia*) were paired and vertically situated on the palmar surface of the fetlock joint. It was pyramidal in shape with notched base in rabbit while in cat it was elongated. The distal sesamoid (*Os sesamoideum distal*) was single and transversely situated on the coffin joint. It was shuttle-shaped in rabbit, whereas in cat it was absent (Fig. 5G and H).

Discussion

Aspinall et al. [4] in cat reported that the pubis was not involved in the formation of the acetabulum of the hip joint. Moreover, Cruise and Nathan [11] recorded that, the presence of a small accessory bone in rabbit, osacetabulum,

that form the acetabulum, by way of the ischium and ilium. These previous observations were in disagreement with our study in both species and we added that the acetabular notch in rabbit was converted into a foramen. On the other hand, Casteleyn et al. [5] in common marmoset (*Callithrix jacchus*) clarified that the acetabulum was deep and contained a lunate articular surface which was intermittent by an acetabular notch and he added that the dorsal ischiatic spine was distinct. But we observed that this spine was thin elevated in rabbit and low everted one in the cat.

Concerning the different shapes of the obturator foramen, we observed that it was large oval in rabbit as well as [11] but it was very large in common marmoset [5] and elliptical in the cat.

The position of the femur was horizontal in rabbit which adapted their standing position while in the cat it was oblique cranioventral as other domestic animals [12]. The femur had marked major and minor trochanters and the third trochanter was absent in common marmoset [5] as our work in the cat. The third trochanter was present in mole-rats on the proximal third of the femur [3] similar to in our observations in the rabbit. Furthermore, the occurrence of three trochanters on the femur was stated by Salami et al. [13] in the African giant pouched rat (*Cricetomys gambianus*). Presence of femoral condyles and the patellar groove on the femur leads to complexity of its distal epiphysis [14]. The presence of the fabellae in both species in this study was in agreement with Casteleyn et al. [5] in common marmoset. Humans had a round, triangular, or rectangular ossified lateral fabella [15]. Patella varied in its shape as it was ovoid in common marmoset [5] but it was triangular in rabbit and pyramidal in the cat in our research.

Tibia and fibula were separated by an interosseous space and were not fused [5] in common marmoset similar to the present study in the cat. But the fibula was fused with the tibia for over half its length [1,11] in rabbit as our result.

Regarding tarsal bones, they were six in rabbit go hand with [11]. While Casteleyn et al. [5] in marmoset mentioned that, the tarsal bones were seven arranged in three rows; talus and calcaneus in the crural row, a reduced middle central tarsal one, and four bones in the metatarsal row. Rodentia order had similarly in the number of tarsal bones as eight in two rows [3,13]. But their arrangement was differed as in two rows, three proximally and four distally and a central one was in the distal of the talus in mole-rats [3]. Even as in the African giant pouched rat, Salami et al. [13] revealed that tarsal bones were four proximally and four distally.

Cruise and Nathan [11] clarified that, there were four well-developed metatarsals (II–III–IV–V) with an immature metatarsal I unlike the rabbit in this paper, metatarsal

one was absent but in cat there was a rudimentary metatarsal I. They added that the digits were four each with three phalanges as our observation in both animals. Although Ozkan [3] in mole rat and Casteleyn et al. [5] in marmoset stated that, the digits were five in number. The latter author added that the medial digit had two phalanges, its distal phalanx was flat, blunt, and covered by a flat nail. Whereas the claws of the other four digits were curved and sharp.

There were axial and abaxial ovoid sesamoid bones on the plantar sides of the distal extremities of the metatarsal bones and there were no distal sesamoid bones [5] as our result in cat but differed from that of rabbit which it possessed distal sesamoids.

Concerning the shape of the distal phalanx which was triangular with broad or more pointed unguicular process in rabbit and cat, respectively that similar to the attribution of [16] in African giant rat to the burrowing habit.

Conclusion

There were a lot of variations between the bones of the pelvic limbs of rabbits and cats, which inspired us an idea for the later research by comparing their musculature in both species.

Conflict of Interests

The authors affirm that they have no conflict of interest.

Authors' contribution

Both authors have done all the practical steps together as well as writing the paper and reviewing English, also reading and approving the final manuscript.

References

- [1] Okerman L. Anatomical peculiarities. In: Diseases of domestic rabbits. 2nd edition, Blackwell Scientific Publications, Oxford, London, Edinburgh Boston, Melbourne, Paris, Berlin, Vienna, pp 10–14, 1994.
- [2] Abidu-Figueiredo M, Xavier-Silva B, Cardinot T, Babinski M, Chagas M. Celiac artery in New Zealand rabbit: anatomical study of its origin and arrangement for experimental research and surgical practice. *Pesquisa Vet Brasil* 2008; 28:237–40. <https://doi.org/10.1590/S0100-736X2008000500002>
- [3] Özkan ZE. Macro-anatomical investigations on the hind limb skeleton of mole-rat (*Spalax leucodon* Nordmann). *Veterinarski Arhiv* 2002; 72(3):159–66.
- [4] Aspinall V, Cappello M, Phillips C. Introduction to veterinary anatomy and physiology textbook. 3rd edition, Elsevier, Edinburgh, pp 166–70, 2015.
- [5] Casteleyn C, Bakker J, Breugelmans S, Kondova I, Saunders J, Langermans JAM, et al. Anatomical description and morphometry of the skeleton of the common marmoset (*Callithrix jacchus*). *Lab Anim* 2012; 46:152–63. <https://doi.org/10.1258/la.2012.011167>
- [6] Hudson LC, Hamilton WP. Atlas of the feline anatomy for veterinarians. W.B. Saunders Company, Philadelphia, London, Toronto, Montreal, Sydney, Tokyo, pp 24–39, 1993.
- [7] McCracken TO, Kainer RA, Carlson D. Color atlas of small animal anatomy: the essentials. 1st edition, Blackwell Publishing, Ames, IA, 2008.
- [8] Hall LW, Clarke KW, Trim CM. Veterinary anesthesia. 10th edition, WB Saunders. Harcourt Publishers Limited, New York, pp 441–66, 2001.
- [9] Onwuama KT, Salami SO, Ali O, Nzalok, JO. Effect of different methods of bone preparation on the skeleton of the african giant pouched rat (*Cricetomys gambianus*). *Int J Morphol* 2012; 30(2):425–7. <https://doi.org/10.4067/S0717-95022012000200011>
- [10] Nomina Anatomica Veterinaria. 5th edition, prepared by the International Committee on Veterinary Gross Anatomical Nomenclature (I.C.V.G.A.N.) and authorized by the General assembly of the World Association of Veterinary Anatomists (W.A.V.A.), Knoxville, TN (USA). Published by the Editorial Committee, Hannover, Columbia, Ghent and Sapporo, pp 18–23, 2012.
- [11] Cruise JL, Nathan RB. Anatomy. In: Manning PJ, Ringler DH, Newcomer CE (eds.). The biology of the laboratory rabbit, 2nd edition, Academic Press, London, pp 47–61, 1994. <https://doi.org/10.1016/B978-0-12-469235-0.50009-9>
- [12] Dyce KM, Sack WO, Wensing CJG. Textbook of veterinary anatomy. 4th edition, WB Saunders Company, Philadelphia, 2010.
- [13] Salami SO, Onwuama KT, Byanet O, Ibe SC, Ojo SA. Morphological studies of the appendicular skeleton of the African giant pouched rat (*Cricetomys gambianus*) part (ii) pelvic limb. *J Vet Med Anim Health* 2011;3(7):88–93.
- [14] Pazzaglia UE, Sibilia V, Congiu T, Pagani F, Ravanelli M, Zarattini G. Setup of a bone aging experimental model in the rabbit comparing changes in cortical and trabecular bone: morphological and morphometric study in the femur. *J Morphol* 2015; 276:733–47. <https://doi.org/10.1002/jmor.20374>
- [15] Corvalan C, Tang C, Robinson M. Fabella and cyamella of the human knee joint: discovery by dissection and ultrasound examination. *Eur J Anat* 2018; 22(2):103–9.
- [16] Olude MA, Olopade JO, Mustapha OA. Macro-anatomical investigations of the skeletons of the African giant rat (*Cricetomys gambianus* Waterhouse): Pelvic limb. *Eur J Anat* 2009; 13(3):127–31.