

ORIGINAL ARTICLE

Prevalence and histopathology of Sarcocystosis in slaughtered carcasses in southeast Iran

Mahdi Khoshsima Shahraki¹, Abdolhakim Ghanbarzahi², Mansour Dabirzadeh³

¹Msc of Parasitology, Department of Parasitology, Faculty of Medical Science, Zabol Medical University, Zabol, Iran

²Msc of Psychology, Iranshahr University of Medical Science, Iranshahr, Iran

³Associate Professor of Parasitology, Department of Parasitology, Faculty of Medical Science, Zabol Medical University, Zabol, Iran

ABSTRACT

Objective: *Sarcocystis* spp. are common parasites and in terms of economics and pathogenicity in domestic animals is important. The purpose of this work was to define the rate of contamination of slaughtered carcasses of cattle to *Sarcocystis* using digestive and histopathological methods in southeast Iran.

Material and Methods: In this descriptive laboratory study for 1 year, 500 carcasses were examined and isolated bradyzoites of *Sarcocystis* with the digest method. Also, tissue samples from the esophagus and diaphragm were considered for pathologic studies and stained with hematoxylin and eosin of sections of histopathological.

Results: The results showed that the highest contaminations were in imported male animals aged 2–3 years old in the spring. There was a significant difference ($p < 0.05$) in the prevalence rate with the sex and race of cattle but no significant difference ($p > 0.05$) in the prevalence rate with age and season.

Conclusion: Infection with *Sarcocystis* is common in oxen in this region. The imported cattle are more infected. It seems that racing and the environmental condition affect the prevalence of *Sarcocystis*.

ARTICLE HISTORY

Received March 17, 2018

Revised April 28, 2018

Accepted May 01, 2018

Published November 07, 2018

KEYWORDS

Slaughter; cattle; histopathology; *Sarcocystis*



This is an Open Access article distributed under the terms of the Creative Commons Attribution 4.0 Licence (<http://creativecommons.org/licenses/by/4.0>)

Introduction

The genus *Sarcocystis* has the most prevalent and it is an obligatory two-host parasite. Herbivores as the interface host, infected through contaminated water and food with excreted oocyst by the infected final host. As the final host, carnivorous or omnivorous get this parasite through consumption of infected tissue [1–3].

More than 150 species of *Sarcocystis* were known as parasites of pets and wildlife [4]. Clinical sarcocystosis is relatively rare in cattle [5]. Clinical signs usually include weight loss, abortions, reduced milk production, and death in cattle [4,6]. These symptoms occur during the development of second-generation intravascular meronts [4]. The most common pathological changes associated with *Sarcocystis* occur in the intermediate host, the tissue cysts contain bradyzoites in the muscles, although

encephalitis sometimes occurs with this parasite in sheep (*Sarcocystis ovis*) and horse (*S. neurona*) [7,8].

To identify different species of *Sarcocystis* cysts (sarcocysts) in different animals, ultrastructural studies are performed on the cyst wall of this parasite [9] *Sarcocysts* infections are common in cattle around the world [5]. The six species of *Sarcocystis* reported in the cow include *S. cruzi*, *S. hirsuta*, *S. rommeli*, *S. heydorni*, *S. hominis*, and *S. bovifelis* [5,10]. Of these species, *S. cruzi* is the most pathogenic [5].

The prevalence of *Sarcocystis* species in young cattle muscle in most parts of the world is about 100% [5,8]. On examination after death, it can only detect small quantities of animals that have lesions in green to yellow areas of very small size up to 15 cm [11]. Responsible for microscopic

Correspondence Mansour Dabirzadeh ✉ mdabirzadeh20002000@yahoo.com 📧 Department of Parasitology, Faculty of Medical Science, Zabol Medical University, Zabol, Iran.

How to cite: Shahraki MK, Ghanbarzahi A, Dabirzadeh M. Prevalence and histopathology of *Sarcocystis* in slaughtered carcasses in southeast Iran. *J Adv Vet Anim Res* 2018; 5(4):381–7.

lesions is eosinophilic myositis, which is associated with the presence of *Sarcocystis* spp. [5,8].

In most cases, *Sarcocystis* muscle cysts are visible only with an optical microscope. However, the definitive identification of *Sarcocystis* at the surface of the species requires an electron microscope or molecular detection method [5,12].

Material and Methods

Study of the area

Sistan-Baluchestan provinces have located in southeastern Iran with an area of 187,502 km² that more than 11% of Iran is involved. A Sistan region in north and Baluchistan region is located in the south of the province. Sistan consists of Zabol and its surrounding cities, and Baluchistan includes southeastern cities from Zahedan to Chabahar. This study was carried out in the city of Sarbaz, Iranshahr, Zabol, and the surrounding towns.

Sampling

During 1 year, 500 carcasses were selected randomly (20 carcasses each time) from carcasses in Iranshahr and Zabol and were sampled from the esophagus and diaphragm. The age of the animals recorded was based on dental formula and sex of the carcass from the genitals. Also, the sampling season and livestock identification were recorded, whether native or not.

Method

After sampling, the specimens were transferred to the Laboratory of Department of Parasitology, Faculty of Medicine, Zabol Medical University and necessary tests were carried out.

In the laboratory, 20 gm of muscles was crushed and digested for 30 min at 40°C in 50 ml of digestion medium (containing 1.3 gm pepsin, 3.5 ml HCl, and 2.5 gm NaCl in 500 ml of distilled water). Then, solution was centrifuged at 2,500 rpm for 5 min. The sediment after stained with hematoxylin and eosin (H&E) examined microscopically at 400× magnification. In case of being positive, under the microscope, free bradyzoites were seen as a banana body.

Histopathological study

In this study, cattle which are suspected to have disease in esophagus and/or diaphragm or have problems with vital organs were examined. So the case study was divided into small slices of 1 × 1 cm which preserved in 10% formalin and put in paraffin, four of these samples were marked by H&E for further histopathological examination.

Statistical analysis

Statistical analysis was performed using SPSS version 20 software (SPSS Inc., Chicago, IL). To analyze the data, descriptive statistics such as abundance and percentage of frequency and inferential statistics such as *t*-test, two independent samples, and one-way analysis of variance were used.

Results and Discussion

According to the results, 58 heads of cows were females and 442 males. The most contamination is related to the male with a frequency of 400 heads.

In relation to the breed of cows, also 116 heads of native cows and 384 heads of imported animals that the highest infection rate of the imported breed with 350 heads.

Each of the investigated cows was classified into groups according to the age of the year (<1, 1–2, 2–3, and >3) that in the first group, 51 heads of cows and oxen, the second group has 122 heads, the third group has 177 heads, the fourth group has 150 heads, and the most contamination is related to the third group with 154 heads. Also, in relation to the seasons studied, in spring 169 heads, summer 173, autumn 77, and winter 81 heads that the highest infection was observed in the spring with a frequency of 155 heads (Table 1).

There was a significant difference ($p < 0.05$) in the prevalence rate with the sex and race of cows (Figures 1 and 2) but no significant difference ($p > 0.05$) in the prevalence rate with age and season (Figures 3 and 4).

Pathology results

As shown in Figures 5 and 6, inflammation cells, such as lymphocyte cells, plasma cells, macrophage cells, and also necrosis in this segment can be viewed. In granulomatous of myositis, muscle wasting and infiltration of inflammatory cells can be seen.

Table 1. Relationship between *Sarcocystis* and demographic factors.

p value	Statistical test	Sarcocystis			
		Positive	Negative		
0/000	13/80	91 (78/4)	25 (21/6)	Native	Race
		350 (91/1)	34 (8/9)	Non-native	
0/352	3/26	43 (84/3)	8 (15/7)	<1	Age
		106 (86/9)	16 (13/1)	1–2	
		154 (87/0)	23 (13/0)	2–3	
		138 (92/0)	12 (8/0)	>3	
0/000	19/32	41 (70/7)	17 (29/3)	Female	Sex
		400 (90/5)	42 (9/5)	Male	
0/163	5/12	155 (91/7)	14 (8/3)	Spring	Season
		148 (85/5)	25 (14/5)	Summer	
		70 (90/9)	7 (9/1)	Autumn	
		68 (84/0)	13 (16/0)	Winter	

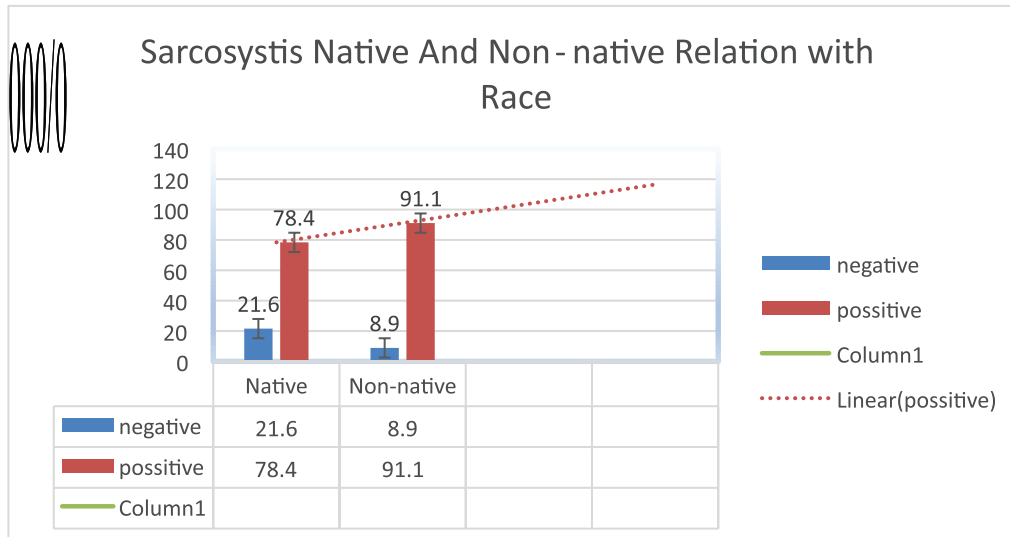


Figure 1. Sarcocystis infection rate relationship with race (p value = 000.01).

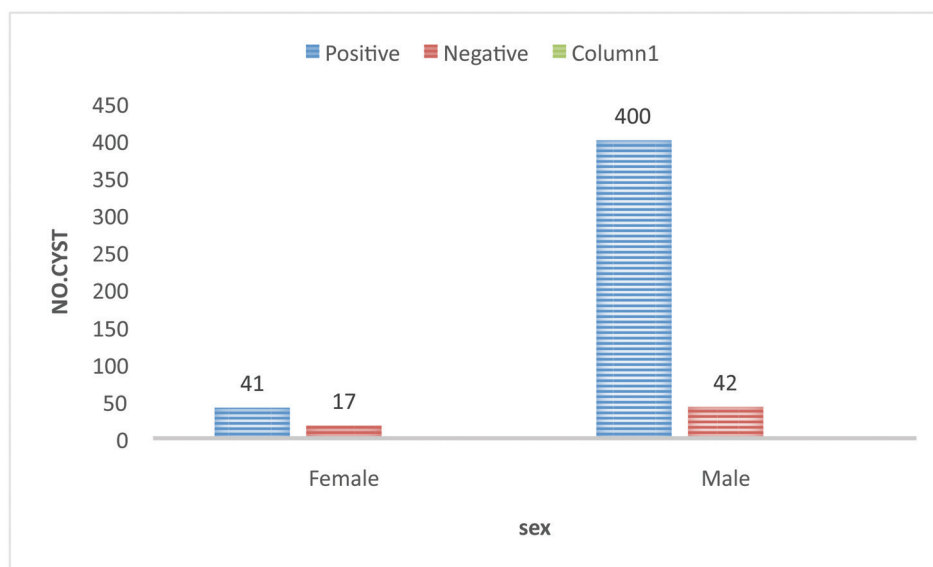


Figure 2. Sarcocystis infection rate relationship with sex (p value = 0.00).

Sarcocystis is a common disease between humans and animals. This disease is very important for veterinary medicine, due to many economic losses and human health. Sarcocystis was first reported by Meisher in domestic mice in 1843 [13].

In this study, of the 500 carcasses of the cattle examined, 88.2% were contaminated with sarcocystosis. Shekarforoush et al. [14] reported contamination of 100% of the cows studied in southern Iran.

The frequency of the main hosts of microscopic species of the parasite, human, and canine, results from the v of meat and entrails of cattle in raw and semi-cooked by humans and

dogs. Releasing livestock on the environment, the slaughter of animals outside the slaughterhouse, the existence of stray dogs and their access to slaughterhouse waste and meat lesions, and the pollution of water and fodder of livestock with sewage and waste of dogs are probably due to the high prevalence of infection with this parasite.

In this study, macroscopic cysts were not seen. This finding is consistent with the results of Shekarforoush et al. [14]. But in a study in Egypt, Ahmed et al. [15], the frequency of macroscopic cysts was 7.5% in cattle.

They interpreted that the lack of macroscopic cyst is because of the unfavorable weather conditions for the

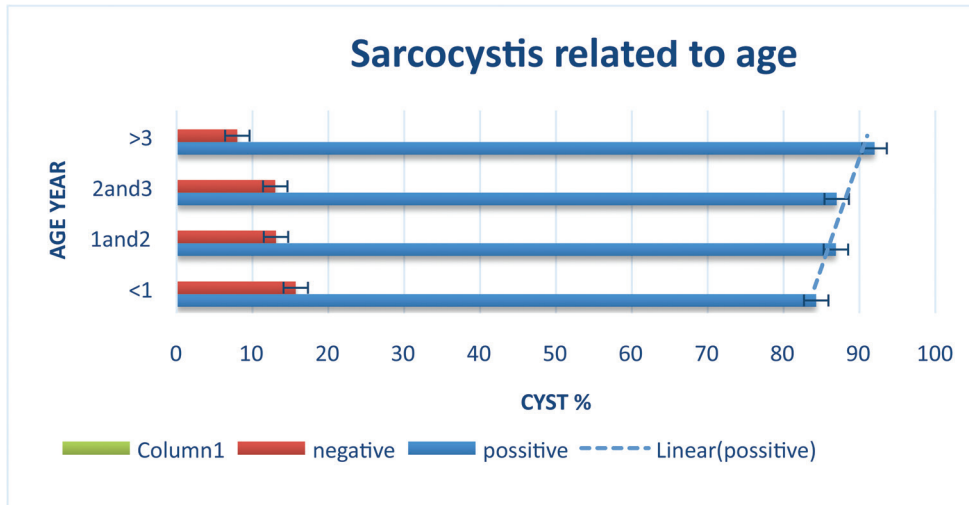


Figure 3. Sarcocystis infection rate relationship with age (p value = 0.352).

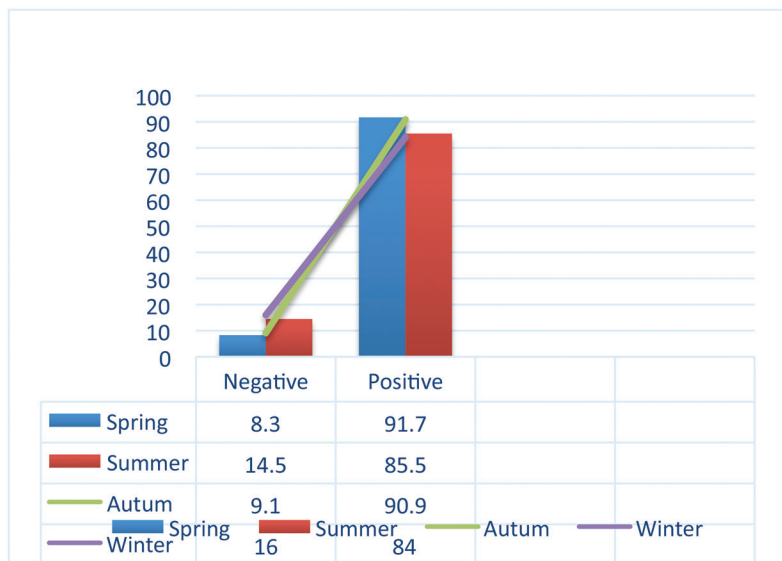


Figure 4. Sarcocystis infection relationship with a season of the year.

survival of cysts in Egypt [15]. This state of affairs may be corrected the cause in our regional field as well.

It seems that due to the low prevalence of macroscopic cysts in our study and similar studies, is the low prevalence of *S. felis* compared to *S. canis*. Dissemination of cat stool compared to dogs in rangelands is less compared with the stool of a dog. Due to more shepherd dog companions with animal herds, and it may be that dog's sporocysts to be more access to be infected [13].

Of these samples that were positive, 350 specimens were imported cows and 91 specimens were collected from native cattle. There was a significant difference between the prevalence of Sarcocystosis and Race livestock.

In this study, the digestive method was used to detect parasites. Shekarforoush et al. [14], also reported that the digestive method is more accurate than the tissue expansion method. In the tissue extension method, some contaminated specimens may not be detected.

In this study, parasite contamination was reported in carcasses of cows aged 2–3 years, however, no significant difference was found between age and parasite prevalence. This finding is consistent with the results of the study by Taib et al. [16].

In the present study, Sarcocystis infection was more common in males and according to the statistical results, this difference was significant. This finding is not consistent with

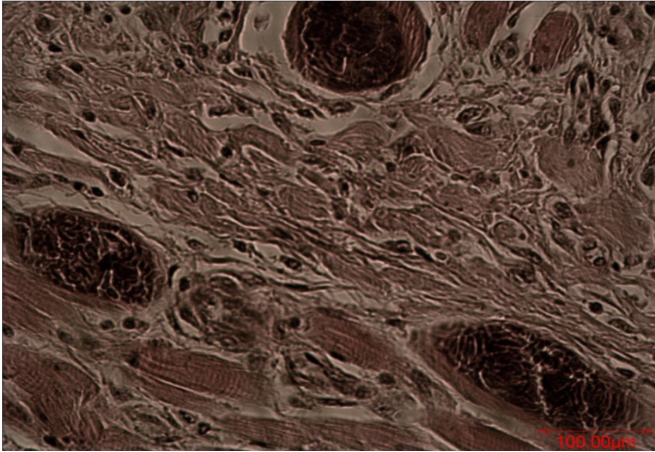


Figure 5. Microcyst with muscle wasting and muscle fibrosis (replacing connective tissue in muscle wasting).

the results of a study in Egypt, the prevalence of infection in women was higher [15] and Taib et al. [16] could not report significant differences between sexes and the frequency of parasites. In our study, the frequency of *Sarcocystis* infection was higher in the spring; however, this difference was not statistically significant. Also, in another study in northwestern Iran [17], they could not report significant differences between the season and the frequency of parasites. But the frequency of *Sarcocystis* infection was higher in summer [17]. However, in a study in Egypt, the highest parasite outbreak was reported in June and the lowest in April [15].

In this study, the esophagus and diaphragm muscles were studied. In this regard, Taib et al. [16] reported that the esophagus is the most muscle that is infected with *sarcocystis* microscopic cysts and then the diaphragm is after that. Also, in a study in Kerman, the esophageal and diaphragm muscles were used. Researchers have shown that these organs are the most common place for contamination with *Sarcocystis* [13]. In the current document, it was reported that there was a significant relationship between the rates of infection in different parts so that the highest contamination was in the heart (68%) and the lowest in the esophagus (36.6%). In different studies, the degree of contamination in different organs is somewhat different. This difference may be due to contaminating species because any parasite prefers a particular texture for the establishment and formation of cysts. The method of study is also effective in determining the contamination of various organs. After staining and microscopic examination, inflammatory cells such as lymphocyte cells, plasma cells, and macrophage cells were seen. Vangeel et al. [18], after inflammatory infiltration in muscle samples, mostly observed eosinophil granulocytes. In addition, lymphocytes, plasma cells, and macrophages were observed.

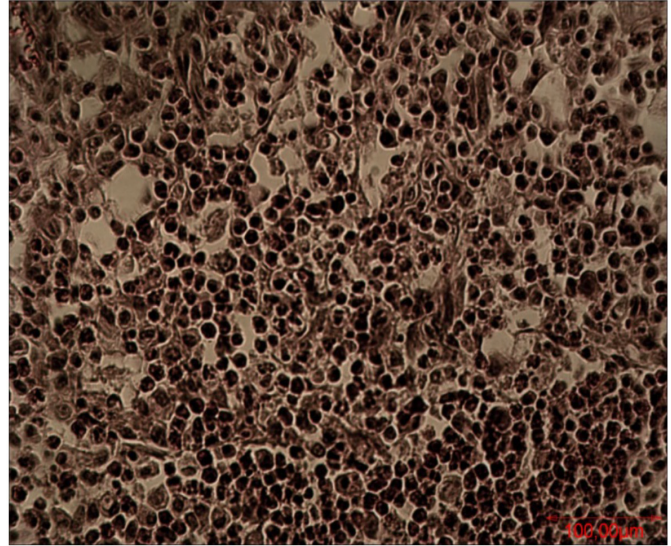


Figure 6. Picture of microcysts in esophagus and granulomatous of chronic myositis.

Conclusion

Infection with *Sarcocystis spp.* is common in oxen in this region. The imported cattle are more infected. It seems that racing and the environmental condition affect the prevalence of *Sarcocystosis*.

Limitations of the study

Some samples were not completely on access or dismiss during the producer as they need more precaution and time.

Acknowledgments

The authors would like to honor and venerate invaluable efforts of Vice-chancellor of Research and Technology in Zabol Medical University, some authorities that serve us.

Funding

The study was sustained by grants from the deputy of Research by Zabol Medical University.

Conflict of Interest

None.

Authors' contribution

Mahdi Khoshsima Shahraki contributed in sample collection, with Abdolhakim Ghanbarzehi carried out the experimental producers. Abdolhakim Ghanbarzehi helps

for examination of tissues and the collection, Mansour Dabirzadeh as a supervisor, as well as drafting the paper.

References

- [1] Fayer R. *Sarcocystis* spp. in human infections. *Clin Microbiol Rev* 2004; 17(4):894–902; <https://doi.org/10.1128/CMR.17.4.894-902.2004>
- [2] Frenkel J, Smith D. Determination of the genera of cyst-forming coccidia. *Parasitol Res* 2003; 91(5):384–9; <https://doi.org/10.1007/s00436-003-0969-4>
- [3] Xiang Z, Chen X, Yang L, He Y, Jiang R, Rosenthal BM, et al. Non-invasive methods for identifying oocysts of *Sarcocystis* spp. from definitive hosts. *Parasitol Int* 2009; 58(3):293–6; <https://doi.org/10.1016/j.parint.2009.03.004>
- [4] Morsy K, Saleh A, Al-Ghamdi A, Abdel-Ghaffara F, Al-Rasheid K, Bashtar A-R, et al. Prevalence pattern and biology of *Sarcocystis capracanis* infection in the Egyptian goats: a light and ultrastructural study. *Vet Parasitol* 2011; 181(2):75–82; <https://doi.org/10.1016/j.vetpar.2011.05.010>
- [5] Dubey J, Calero-Bernal R, Verma S, Mowery J. Pathology, immunohistochemistry, and ultrastructural findings associated with neurological sarcocystosis in cattle. *Vet Parasitol* 2016; 223:147–52; <https://doi.org/10.1016/j.vetpar.2016.04.025>
- [6] Odening K, Stolte M, Bockhardt I. On the diagnostics of *Sarcocystis* in cattle: sarcocysts of a species unusual for *Bos taurus* in a dwarf zebu. *Vet Parasitol* 1996; 66(1):19–24.
- [7] Formisano P, Aldridge B, Alony Y, Beekhuis L, Davies E, Del Pozo J, et al. Identification of *Sarcocystis capracanis* in cerebrospinal fluid from sheep with neurological disease. *Vet Parasitol* 2013; 193(1):252–5; <https://doi.org/10.1016/j.vetpar.2012.12.016>
- [8] Vangeel L, Houf K, Geldhof P, De Preter K, Vercruyse J, Ducatelle R, et al. Different *Sarcocystis* spp. are present in bovine eosinophilic myositis. *Vet Parasitol* 2013; 197(3):543–8; <https://doi.org/10.1016/j.vetpar.2013.06.001>
- [9] Abdel-Ghaffar F, Mehlhorn H, Bashtar AR, Al-Rasheid K, Sakran T, El-Fayoumi H. Lifecycle of *Sarcocystis camelicanis* infecting the camel (*Camelus dromedarius*) and the dog (*Canis familiaris*), light and electron microscopic study. *Parasitol Res* 2009; 106(1):189–95; <https://doi.org/10.1007/s00436-009-1648-x>
- [10] Gjerde B, Hilali M, Abbas IE. Molecular differentiation of *Sarcocystis buffalonis* and *Sarcocystis levinei* in water buffaloes (*Bubalus bubalis*) from *Sarcocystis hirsuta* and *Sarcocystis cruzi* in cattle (*Bos taurus*). *Parasitol Res* 2016; 115 (4):1473–92; <https://doi.org/10.1007/s00436-015-4881-5>
- [11] Lindsay DS, Mitchell SM, Yang J, Dubey J, Gogal RM, Witonsky SG. Penetration of equine leukocytes by merozoites of *Sarcocystis neurona*. *Vet Parasitol* 2006; 138(3):371–6; <https://doi.org/10.1016/j.vetpar.2006.01.057>
- [12] Rosenthal BM, Dunams DB, Pritt B. Restricted genetic diversity in the ubiquitous cattle parasite, *Sarcocystis cruzi*. *Infect Genet Evol* 2008; 8(5):588–92; <https://doi.org/10.1016/j.meegid.2008.04.004>
- [13] Levine ND. The taxonomy of *Sarcocystis* (protozoa, apicomplexa) species. *J Parasitol* 1986; 372–382; <https://doi.org/10.2307/3281676>
- [14] Shekarforoush S, Razavi S, Dehghan S, Sarihi K. Prevalence of *Sarcocystis* species in slaughtered goats in Shiraz, Iran. *Vet Rec* 2005; 156(13):418; <https://doi.org/10.1136/vr.156.13.418>
- [15] Ahmed AM, Elshraway NT, Youssef AI. Survey on *Sarcocystis* in bovine carcasses slaughtered at the municipal abattoir of El-Kharga, Egypt. *Vet World* 2016; 9(12):1461; <https://doi.org/10.14202/vetworld.2016.1461-1465>
- [16] Taib M, Harhoura K, Aissi M, Chaouadi M, Djouhri Y. Study of the bovine Sarcosporidiosis in the slaughterhouses of the North of Algeria: case of the Slaughterhouses of El Harrach (Algiers). *Cell Dev Biol* 2016; 5:167.
- [17] Nematollahia A, Khoshkerdar A, Helan JA, Shahbazi P, Hassanzadeh P. A study on the rate of infestation to *Sarcocystis* cysts in supplied raw hamburgers. *J Parasit Dis* 2015; 39(2):276–9; <https://doi.org/10.1007/s12639-013-0339-9>
- [18] Vangeel L, Houf K, Chiers K, Vercruyse J, D'herde K, Ducatelle R. Molecular-based identification of *Sarcocystis hominis* in Belgian minced beef. *J Food Protect* 2007; 70(6):1523–6; <https://doi.org/10.4315/0362-028X-70.6.1523>