

## Pathogenicity and immunosuppressive properties of GM-97 strain of infectious bursal disease virus in commercial broiler chickens

Rozina Murmu<sup>1</sup>, Md. Nazrul Islam<sup>1</sup>, Most. Sogra Banu Juli<sup>1</sup>, Md. Abu Sayed Khan<sup>1</sup>, S.M. Harun-ur-Rashid<sup>1</sup>, Ferdaus Mohd. Altaf Hossain<sup>2</sup> and Md. Masudur Rahman<sup>2\*</sup>

<sup>1</sup>Faculty of Veterinary and Animal Science, Hajee Mohammad Danesh Science and Technology University, Dinajpur-5202, Bangladesh.

<sup>2</sup>Faculty of Veterinary and Animal Science, Sylhet Agricultural University, Sylhet 3100, Bangladesh.

\*Corresponding author's e-mail: [rahmanmm.dpp@sau.ac.bd](mailto:rahmanmm.dpp@sau.ac.bd)

### ABSTRACT

The current study was conducted to evaluate the pathogenicity and immunosuppressive effects of GM-97 strain of infectious bursal disease virus in commercial broiler chickens. A total of 500 broiler chickens were vaccinated with the virus through oral route at 10 and 17 days of age ( $10^2$ - $10^3$  EID<sub>50</sub>/dose). Chickens were also vaccinated with Newcastle disease virus (Hitchner B1) orally at 14 and 21 days old. Chickens were euthanized (at 12, 14, 16, 20, 23, 26 days of age) after measuring body weight. Bursa of Fabricius was examined for any gross lesion, weighed and processed for histological investigations. Bursa to body weight ratio and bursal lesion scoring were made to evaluate pathogenicity of the virus. Blood samples were analyzed for antibody response to ND vaccine virus using HI test. Results showed that the GM-97 strain of IBDV induced mild to moderate depletion of lymphoid cells in the center of bursal follicles and non-significant difference in bursa to body weight ratio amongst vaccinated and unvaccinated chickens. Chickens responded well to ND vaccine by mounting high level of serum NDV specific HI antibody titers. It can be concluded from the present study that GM-97 strain of IBDV has mild pathogenicity but is not immunosuppressive.

### Keywords:

Commercial chicken, GM-97 strain, IBD vaccine, immunosuppression, pathogenicity

Received : 28 January 2014, Revised: 10 February 2014,  
Accepted : 12 February 2014, Published Online: 15 February 2014.

### INTRODUCTION

Infectious bursal disease (IBD) is an acute, highly contagious viral disease of young chickens characterized mainly by severe lesions in the bursa of Fabricius (BF) followed by immunosuppression (Saif, 1994; Lukert and Saif, 1997). Infectious bursal disease virus (IBDV) belongs to the genus *Birnavirus*, sub-genus *Avibirnavirus*, family Birnaviridae. There are two distinct serotypes of IBDV namely serotype 1 and serotype 2. Both serotypes can infect chickens and turkeys but clinical disease is recognized only in chickens (Yamaguchi et al., 1996). Only serotype 1 is virulent for chickens, replicating within the lymphoid cells of the bursa of Fabricius and destroying them and thereby inducing immunosuppression (Lukert and Saif, 2003). Serotype 1 comprises four pathotypes namely classical virulent, attenuated strains, very virulent and antigenic variant (van den Berg, 2000; Lukert and Saif, 2003).

IBDV is highly infectious and very resistant to inactivation. There is no alternative of vaccination in the prevention of IBD or Gumboro disease (Lukert and Saif, 1997), although the clinical outbreaks in vaccinated flocks are reported (Hafez et al., 2002; Islam et al.,

2008). In case of using live vaccines to control IBD, neutralization of vaccine viruses by maternal neutralizing antibodies is considered to be one factor causing vaccination failure. To overcome this problem, relatively virulent strains of vaccine viruses with higher residual pathogenicity (e.g. intermediate strains, intermediate plus strain) have been introduced (Kouwenhoven and van den Bos, 1994). The better protection with more virulent strain of IBDV is due to more antigenic stimulation based on higher and longer replication in lymphoid tissues (Rautenschlein et al., 2001). However, these intermediate vaccine strains may produce moderate to severe bursal lesions and immunosuppression in vaccinated chickens as reported by many researchers (Mazariegos et al., 1990; Franciosini and Coletti, 2001; Boudaoud and Alloui, 2008). In many countries including Bangladesh, commercially available live IBDV vaccines containing intermediate plus strains are widely used in commercial chickens to get better protection against currently circulating very virulent IBDV. The present study was designed to investigate the pathogenicity and immunosuppressive properties of GM-97 strain of IBDV in commercial broiler chickens under field condition.

## MATERIALS AND METHODS

**Experimental chickens and their management:** A total of 500 unvaccinated Cobb-500 day old chicks (DOC) were received from the Nourish Poultry and Hatchery Ltd., Bangladesh. The chicks were reared in a relative isolation under farming condition at Polash Poultry Farm, Saidpur under Nilphamari district of Bangladesh. The farm was thoroughly cleaned, disinfected with a household phenolic disinfectant (Phenyl) and fumigated before placing the DOC in the farm. Chicks were provided commercial feed and water *ad libitum* under relatively optimum temperature and humidity conditions and strict bio security measures were adopted.

**Vaccine and vaccination schedule:** A freeze-dried live vaccine (HIPRAGUMBORO®GM97, Hipra, Bangladesh Ltd.) containing the GM-97 strain of IBDV was used to vaccinate the birds. The chickens were immunized orally at 10 days of age through drinking water ( $10^2$ - $10^3$  EID<sub>50</sub>/dose) and boosted at 17 days old (7 days post-primary vaccination) using the same dose and route of administration as recommended by the manufacturer. Another freeze-dried live vaccine (Hitchner B1 strain ND Vaccine, Hipra, Bangladesh Ltd.) was used to immunize chickens against Newcastle disease (ND) at 14 and 21 days of age through drinking water ( $7.5 \text{ Log}_{10}$ EID<sub>50</sub>/dose). A group of chickens (n=10) were

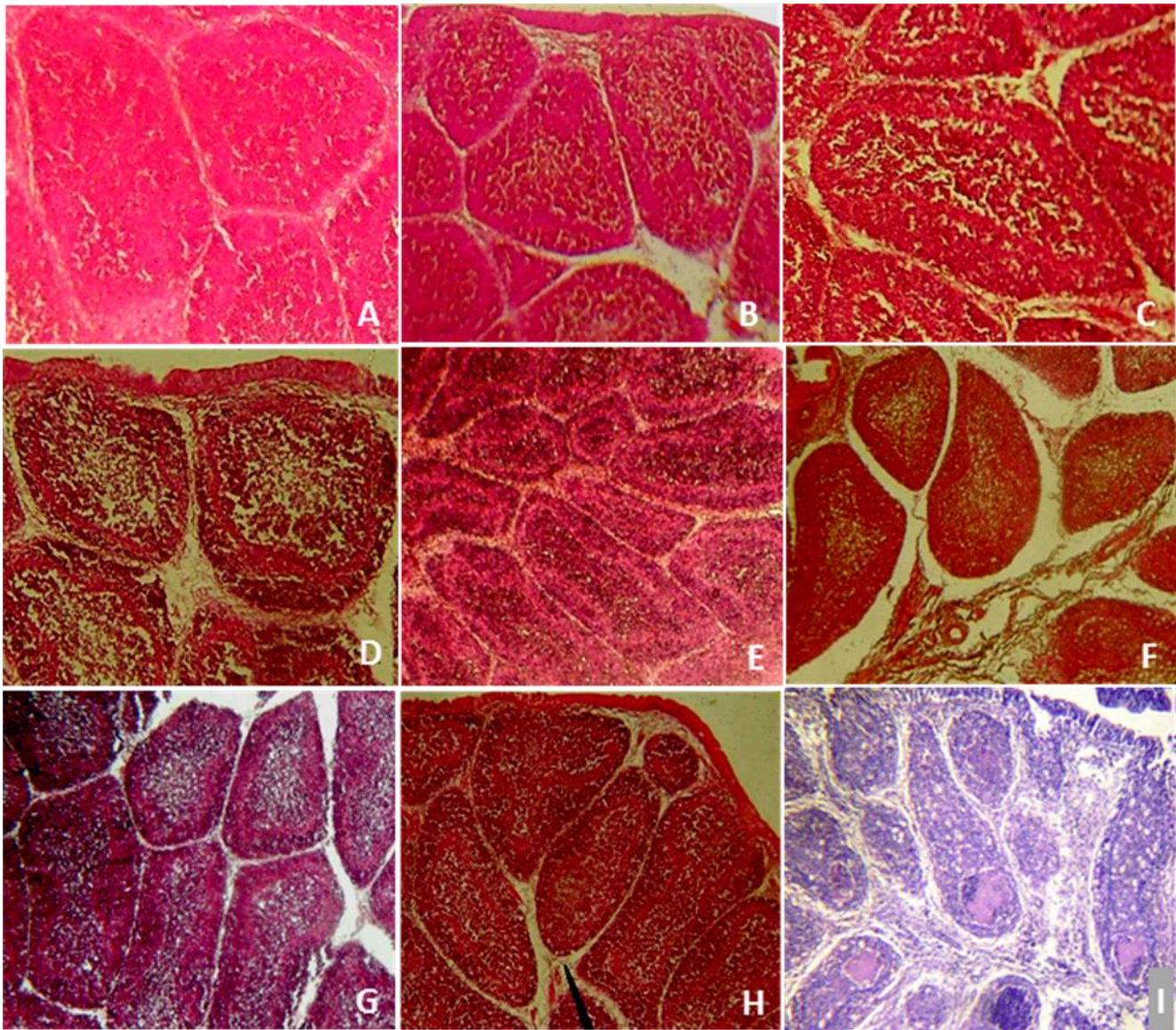
reared in the same farm in relative isolation without any vaccination and considered as negative control group.

**Necropsy and bursa-body weight (B/BW) ratio:** At day 2, 4 & 6 post-primary vaccination (DPPV) and day 3, 6 & 9 post-booster vaccination (DPBV) of IBD, birds (n=3/day) were brought to the Laboratory of Pathology, Hajee Mohammad Danesh Science and Technology University (HSTU), Dinajpur-5202, Bangladesh for necropsy examination. Additionally, three unvaccinated naïve chickens (10 days old, reared in the same farm) and three IBD affected chickens (23 days old, 3 days after IBD outbreak) were considered as negative and positive control, respectively. IBD affected chickens were collected from a broiler farm where an IBD outbreak occurred as confirmed by gross and histopathology. Necropsy was performed as per standard procedure (Charlton, 2000) and the gross lesions were recorded. Each chicken was weighed before euthanasia and gross lesions were recorded at necropsy. The bursa of Fabricius was weighed and the average B/BW ratio was determined according to the method described elsewhere (Tanimura et al., 1996).

## Histopathological study and scoring of bursal lesions:

At necropsy, the bursa of Fabricius was collected and preserved in 10% formalin for histopathological studies. The fixed tissue samples were further processed, embedded in paraffin, sectioned and stained with hematoxylin and eosin (H&E) as per previously described method (Bancroft and Gamble, 2008). The sections of stained bursal tissues were studied under light microscope and bursal lesions were recorded and scored as follows: 0, apparently normal lymphoid follicles; 1, mild lymphoid depletion; 2, moderate lymphoid depletion; 3, severe lymphoid depletion; 4, atrophy of follicles with or without cystic spaces (Raue et al., 2004).

**Hemagglutination inhibition (HI) assay:** To evaluate immunosuppressive effects of IBDV GM-97 vaccine strains in vaccinated chickens over ND vaccine, blood for sera was collected 7 day post-primary and 7 & 14 days post-booster vaccination of ND. Twenty chickens were considered for blood collection at each time point. HI test was performed using a method described elsewhere (Rahman et al., 2012) to determine NDV specific HI antibody titers in sera of ND-vaccinated chickens. The geometric means of serum HI titers were defined as the reciprocal logarithm in a base of 2 of the highest serum dilution completely inhibiting agglutination.



**Figure 1. Histopathology of bursa of Fabricius of naïve, vaccinated and IBD affected chickens.** (A) Normal lymphoid follicle in bursa of Fabricius of naïve chicken at 10 days old. (B-H) Histopathological lesions of bursa of Fabricius of vaccinated chickens at different time points: mild lymphoid depletion at 2 DPPV (B), moderate lymphoid depletion without cellular infiltration in the interfollicular space at 4 DPPV (C & D), mild to moderate lymphoid depletion at 6 DPPV (E), mild depletion of lymphoid cells from center of the bursal follicles at 3 DPBV (F), mild depletion of lymphoid cells from center of the bursal follicles and few normal lymphoid cells in focus at 9 DPBV (H). (I) Histopathological lesions of bursa of Fabricius of IBD affected chicken: distended interfollicular spaces, mild to moderate follicular atrophy, mild to moderate lymphocytic depletion, edematous fluid within the follicles and reactive cells infiltration in the interfollicular spaces. The histopathological pictures are representative of sections derived from three chickens in each case (H&E, 40 x).

**Statistical analysis:** Where specified, the data were analyzed for statistical significance using an unpaired two-tailed Student's *t*-test. A *p*-value <0.05 was considered as significant.

## RESULTS

**Clinical manifestations of the experimental chickens:** There was no visible clinical manifestation in naïve and

vaccinated chickens (at all sampling occasions). The chickens naturally affected with IBD at another farm showed varying degrees of inappetence, reluctance to move, drowsiness, severe depression and whitish diarrhea culminating in death.

**Necropsy and gross lesions:** Gross lesions in naïve and vaccinated chickens (at all sampling occasion) were indistinct but typically IBD affected chickens showed

**Table 1: Bursa-body weight ratios of naïve, vaccinated and IBD affected chickens**

Status of Chicken	Age at sampling (in days)	Bursa-body weight Ratio (Mean ± SE)	<i>p</i> -value	Level of significance
Naïve	10	1.99±0.15	0.0044	**
Primary Vaccination (at 10 days old)	12 (2 DPPV)	2.98±0.09	0.0256	*
	14 (4 DPPV)	3.19±0.03	0.2144	NS
	16 (6 DPPV)	2.44±0.34	0.0129	**
Booster Vaccination (at 17 days old)	20 (3 DPBV)	2.45±0.11	0.0051	**
	23 (6 DPBV)	2.24±0.41	0.0041	**
	26 (9 DPBV)	2.38±0.55	0.0036	**
IBD affected	23 (3 DPI)	2.45±0.09	-	-

Vaccinations were performed with live IBDV-GM97 strain (HIPRAGUMBORO®GM97) in drinking water; DPPV=Days post-primary vaccination; DPBV=Days post-booster vaccination; Three chickens (n=3) were considered at each sampling occasion and *p*-values were calculated compared to IBD affected chickens; NS- Not significant.

**Table 2: Bursal lesion score of naïve, vaccinated and IBD affected chickens**

Status of Chicken	Age at sampling (in days)	Lesion score of individual chicken	Average lesion score (Mean ± SE)	Level of significance ( <i>p</i> -value)
Naïve	10	0, 0, 0	0	
Primary Vaccination (at 10 days old)	12 (2 DPPV)	0, 1, 1	1.33±0.33	
	14 (4 DPPV)	1, 2, 3	2.00±0.58	**
	16 (6 DPPV)	0, 1, 1	0.67±0.33	(0.003)
Booster Vaccination (at 17 days old)	20 (3 DPBV)	1, 1, 1	1.33±0.33	
	23 (6 DPBV)	0, 1, 1	1.33±0.33	
	26 (9 DPBV)	0, 0, 1	1.33±0.33	
IBD affected	23 (3 DPI)	3, 3, 4	3.33±0.33	-

Lesion score 0: apparently normal lymphoid follicles, 1: mild lymphoid depletion, 2: moderate lymphoid depletion, 3: severe lymphoid depletion, 4: atrophy of follicles with or without cystic spaces; *p*-values were calculated compared to lesion score of IBD affected chickens to determine level of significance.

**Table 3: NDV specific HI antibody titers in vaccinated chickens**

Status of Chickens	Sampling occasions	Log <sub>2</sub> HI antibody titer (Mean ± SD)
Primary Vaccination (at 14 days old)	7 days post-primary vaccination	5.25 ± 0.97
	7 days post-booster vaccination	7.75 ± 1.52
Booster Vaccination (at 21 days old)	14 days post-booster vaccination	3.05 ± 1.47

Vaccinations were performed with live Hitchner B1 strain of NDV (Hitchner B1 ND Vaccine) in drinking water. Sera of 20 vaccinated chickens (n=20) were tested at each time point.

swollen, edematous, hemorrhagic and atrophied bursa and varying degrees of hemorrhages in the thigh and breast muscles and at the junction between gizzard and proventriculus (data not shown).

**Bursa-body weight ratios:** Bursa-body weight ratios of naïve, vaccinated and IBD affected chickens were determined. The average bursa-body weight ratios were recorded as 1.99±0.15 (10 DO) in naïve; 2.98±0.09 (2 DPPV), 3.19±0.03 (4 DPPV), 2.44±0.34 (6 DPPV), 2.45±0.11 (3 DPBV), 2.24±0.41 (6 DPBV), 2.38±0.55 (9 DPBV) in vaccinated; and 2.45±0.09 (3 DPI) in IBD affected chickens (Table 1). Significant differences in bursa-body weight ratios existed in naïve and vaccinated chickens at all-time points except 4 DPPV compared to IBD affected chickens.

**Histopathology and bursal lesion scores:** To determine the pathogenicity of IBDV-GM-97 vaccine strain, histopathological study of bursa of Fabricius of vaccinated chickens at different time points were performed. Bursa from naïve and IBD infected chickens were also included in the study as a negative and positive control, respectively. Normal lymphoid follicles were observed in bursa of Fabricius of naïve chickens while in vaccinated chickens mild to moderate depletion of lymphoid cells from center of bursal follicles was noted (Figure 1). However, marked lymphoid depletion and follicular atrophy without the development of follicular cysts were observed in IBD affected chickens. Based on the histopathological study, bursal lesion scores of experimental chickens were made and these are shown in Table 2. Bursa of IBDV

infected chickens showed higher lesion score ( $3.33 \pm 0.33$ ) which differed significantly compared to naïve and vaccinated chickens.

**Evaluation of immunosuppressive effects:** To evaluate immunosuppressive effect of IBDV GM-97 vaccine strain in chickens, IBD-vaccinated chickens were subsequently vaccinated with ND (Hitchner B1) vaccine and antigen specific HI antibody titers were determined. We found better NDV specific HI antibody titers in vaccinated chickens which were 5.25 (7 DPPV), 7.75 (7 DPBV) & 3.05 (14 DPBV) in Log<sub>2</sub> scale (Table 3) indicating no immunosuppression.

## DISCUSSION

Pathogenicity of IBDV-GM97 vaccine strain of HIPRAGUMBORO®GM97 vaccine was evaluated in commercial broiler chickens under farm condition in terms of clinical signs and symptoms, gross morbid lesions, bursa-body weight ratios and histopathological studies of bursal lesions. Immunosuppressive effect of the vaccine virus over ND vaccine was also determined. Our results showed mild pathogenicity of IBDV-GM97 vaccine strain in broiler chickens under farm condition which did not have immunosuppressive effects.

Gumboro disease is a highly fatal disease where the morbidity rate is around 100% (Islam et al., 2008) and mortality rate is variable which may reach up to 80% (van den Berg et al., 1991; Hoque et al., 2001; Islam et al., 2008). Clinical manifestations of the disease include high fever, off feed, reluctant to move, depression, drowsiness, watery diarrhea, vent picking (van den Berg, 2000; Islam et al., 2008). Similar clinical manifestations of the disease with 40 % mortality were observed in the IBD affected farm from where affected chickens were collected and used as positive control. Vaccinated chickens showing different typical clinical signs certainly determine the failure of vaccination (van den Berg et al., 1991; Hafez et al., 2002) which may occur either by one or more factors of vaccine breaks (Ismail and Saif, 1991; Etteradossi, 2001). However, any of the clinical manifestations stated above was not recorded in IBDV-GM97 vaccinated chickens in farm under study and there was no apparent morbidity recorded and mortality rate was zero following vaccination.

Hemorrhage in the skeletal muscle and at the junction between proventriculus & gizzard, varying degrees of bursal lesions, enteritis are common gross morbid lesions of IBD and observation of such lesions in IBD-

vaccinated flock indicates vaccine breaks (Islam et al., 2008) and in unvaccinated flock indicates outbreaks of IBD. In our study, we did not find any relevant gross morbid lesions in vaccinated chickens but we observed typical morbid lesions in chickens of IBD affected farms. Bursa-body weight ratios are the vital factor in determining the pathogenicity of IBDV as there is a proportional relationship between bursa-body weight ratio and the pathogenicity of the virus (Mazariegos et al., 1990). In our study, bursa-body weight ratios of naïve and vaccinated chickens significantly differed from that of IBD affected chickens (Table 1).

Typical histopathological lesions of the bursa of Fabricius of an IBD affected chicken include mild to severe lymphoid depletion, follicular atrophy, cystic formation of follicles and bursal hemorrhage (Rudd et al., 2001; Hoque et al., 2001; Islam et al., 2008). The severity of lesions in the bursa of Fabricius is also proportionally related to the degree of pathogenicity of the virus inoculated or infected naturally. In the present study, bursal lesions in vaccinated chickens were histopathologically characterized as either normal follicles with or without mild to moderate lymphoid depletion without follicular atrophy or the development of cystic follicles (Figure 1). However, the histopathological lesions observed in the bursa of vaccinated chickens did not mean the vaccine breaks or immunosuppression, because the lesions stated here might be developed by the vaccine virus (Rudd et al., 2001; Alves and Percira, 2007; Islam et al., 2008). Indeed, relatively minimal lesion scores were observed in bursa of vaccinated chickens compared to IBD affected chickens (Table 2) which did not evoke immunosuppressive effects as evident by high level of NDV specific serum HI antibody titers after ND-vaccination (Table 3). Maternally derived antibody (MDA) against IBDV lasts for variable times of age of chicks after hatching (Kouwenhoven and van den Bos, 1994; Giasuddin et al., 2003). The existing maternal antibody level in chickens is an important factor causing inactivation of vaccine virus, thereby, reducing the immunogenicity as well as pathogenicity of vaccine virus. Therefore, we vaccinated the chickens against IBD primarily at 10 days old based on the maternal antibody level in day old chicks which ruled out the possibility of inactivation of vaccine viruses by MDA.

## CONCLUSIONS

Based on our findings, the GM-97 strain of IBDV contained in HIPRAGUMBORO®GM97 showed mild pathogenicity in vaccinated chickens which did not

have immunosuppressive effects. However, immunogenicity and protective efficacy of the vaccine virus against currently circulation virulent field strain of IBDV (vvIBDV) need to be further addressed.

## ACKNOWLEDGMENTS

This study was partly supported by the research grant of Hajee Mohammad Danesh Science and Technology University, Dinajpur-5202, Bangladesh. We thank poultry farmers for their participation and cooperation with us.

**Competing interests:** *The authors declare that they have no competing interests.*

## REFERENCES

- Alves FM, Percira VL (2007). Cellulitis associated with lesions of bursa of Fabricius from broiler under sanitary inspection. *Rivista Brasileira de Ciencia Veterinaria*, 14: 23-27.
- Bancroft JD, Gamble M (2008). *Theory and Practice of Histological Techniques*. Elsevier Health Science; pp 53-105.
- Boudaoud A, Alloui N (2008). Evaluation of the safety of live attenuated vaccine viruses against infectious bursal disease (Gumboro disease) in conventional broiler chicks. *Revue scientifique et technique*, 27: 793-802.
- Charlton BR (2000). Bacterial Diseases. In: *Avian Disease Manual* (5<sup>th</sup> edn). The American Association of Avian Pathologists. USA; pp 103-1013.
- Eterradossi N (2001). Major advances in infectious bursal disease virus (IBDV) research since the first international IBDV/CIAV symposium (Rauischholzhausen, Germany, 1994). *Proceeding of the II. International Symposium on Infectious Bursal Disease and Chicken Infectious Anaemia*, held on 16-20 July, 2001, at Rauischholzhausen, Germany; pp 6-23.
- Francosini MP, Coletti M (2001). Serological, histological and immuno-histochemistry studies on infectious bursal disease vaccine strain with residual pathogenicity. *Immunosuppressive viral diseases in poultry*, Proceedings 1999. European Commission, COST Action 839; pp 199-206.
- Giasuddin M, Alam J, Islam MR, Rahman, MM (2003). Epidemiological investigation of infectious bursal disease in Bangladesh. 3<sup>rd</sup> International Poultry Show and Seminar. February 28 - March-2, 2003. Worlds Poultry Science Association. Bangladesh Branch; pp 99-103.
- Hafez HM, Prusas C, Raue R (2002). Very virulent infectious bursal disease virus (vvIBDV) in vaccinated broiler flock: Course of the disease, identification and characterization of the isolated strain. *COST Action 839 Immunosuppressive viral diseases in Poultry*. "Molecular Markers in IBDV and CAV" 25-28 April, 2002. Leipzig, Germany; pp 301-312.
- Hoque MM, Omar AR, Chong LK, Hair-Bejo, Aini I (2001). Pathogenicity of Sspl-positive infectious bursal disease virus and molecular characterization of the hypervariable region. *Avian Pathology*, 30: 369-380.
- Islam MN, Rashid SMH, Hoque MF, Juli MSB, Khatun M (2008). Pathogenicity of IBDV related to outbreaks in the vaccinated flocks and the causes of vaccination failure. *Journal of Innovation and Development Strategy*, 2: 22-30.
- Ismail NM, Saif YM (1991). Immunogenicity of IBDV in chickens. *Avian Diseases*, 35: 460-469.
- Kouwenhoven B, van den Bos J (1994). Control of very virulent infectious bursal disease (Gumboro Disease) in the Netherlands with more virulent vaccines. *Proceedings of the International symposium on infectious bursal disease and chicken infectious anaemia*. Rauischholzhausen, Germany; pp 262-271.
- Lukert PD, Saif YM (1997). Infectious bursal disease. In: *Diseases of Poultry* (Calnek BW, Barnes HJ, Beard CW, McGougald LR, Saif YM Ed). Iowa State University Press, Ames. Iowa; pp 721-736.
- Lukert PD, Saif YM (2003). Infectious Bursal Disease. In: *Diseases of Poultry* (Saif YM, Barnes HJ, Fadly AM, Glisson JR, McDougald LR, Swayne DE, ed). Iowa State Press, Ames, Iowa; pp. 161-179.
- Mazariegos LA, Lukert PD, Brown J (1990). Pathogenicity and immuno-suppressive properties of infectious bursal disease "intermediate" strains. *Avian Diseases*, 34: 203-208.
- Rahman MM, Uyangaa E, Han YW, Kim SB, Kim JH, Choi JY, Eo SK (2012). Enhancement of Th1-biased protective immunity against avian influenza H9N2 virus via oral co-administration of attenuated *Salmonella enterica* serovar Typhimurium expressing chicken interleukin-18 and interferon- $\alpha$  along with an inactivated vaccine. *BMC Veterinary Research*, 8: 105.

- Raue R, Islam MR, Islam MN, Islam KM, Badhy SC, Das PM, Muller H (2004). Reversion of molecularly engineered, partially attenuated, very virulent infectious bursal disease virus during infection of commercial chickens. *Avian Pathology*, 33: 181-189.
- Rautenschlein S, Yehand HY, Sharma JM (2001). A comparison of the immunopathogenesis of different IBDV strains. Proceeding of the II. International Symposium on Infectious Bursal Disease and Chicken Infectious Anaemia, held on 16-20 July, 2001, at Rauschholzhausen, Germany; pp 311-323.
- Rudd M, Heine H, Parede L, Sapats S I, Ignjatovic J (2001). Characterization of an Indonesian very virulent strain of infectious bursal disease virus (IBDV). Proceeding of the II International Symposium on Infectious Bursal Disease and Chicken Infectious Anaemia, held on 16-20 July, 2001, at Rauschholzhausen, Germany; pp 40-50.
- Saif YM (1994). Antigenicity and immunogenicity of infectious bursal disease virus. In: International symposium on infectious bursal disease and chicken infectious anaemia, Rauschholzhausen, Germany; pp 21-24.
- Tanimura N, Tsumakoto K, Nakamura K, Narita M, Maeda M (1995). Association between pathogenicity of infectious bursal disease virus and viral antigen distribution detected by immunohistochemistry. *Avian Diseases*, 39: 9-20.
- van den Berg TP (2000). Acute infectious bursal disease in poultry: a review. *Avian Pathology*, 29: 175-195.
- van den Berg TP, Gonze GM, Meulemans G (1991). Acute infectious bursal disease in poultry: isolation and characterization of a highly virulent strain. *Avian Pathology*, 20: 133-143.
- Yamaguchi T, Knodo T, Inoshima Y, Ogawa M, Miyoshi M, Yanai T, Masegi T, Sukhahi H, Hirai K (1996). In vitro attenuation of highly virulent infectious bursal disease virus: some characteristics of attenuated strains. *Avian Diseases*, 49: 501-509.